



## European Society of Veterinary Clinical Pathology

### MYSTERY CASE SESSION

<b>CONTRIBUTOR NAME</b>	Brodie Reinhart
<b>CONTRIBUTOR EMAIL</b>	bnreinhart@upei.ca
<b>COAUTHORS</b>	Noel Clancey, Emily John, Cornelia Gilroy
<b>COMPANY OR UNIVERSITY</b>	Atlantic Veterinary College, University of Prince Edward Island

**SPECIMEN:** Wright-Giemsa stained, images from smeared cytocentrifuged urine

**SIGNALMENT:** 15 year-old male castrated Shire horse

#### **HISTORY AND CLINICAL FINDINGS:**

The patient presented to the referring veterinarian for a history of chronic urinary incontinence and audible sloshing sounds while trotting. Weight loss was also noted in the previous 6 months. At rest, the owner reported micturition of grossly normal urine with a strong stream. The patient was up to date on vaccinations for tetanus, Eastern and Western Equine Encephalitis, Equine Herpesvirus-1 and Equine Influenza Virus.

The patient was referred to the Atlantic Veterinary College Veterinary Teaching Hospital for further evaluation. On presentation, the patient was alert but mildly restless. Physical examination revealed the patient to be moderately thin with a body condition score of 4/9 and decreased muscle mass over the scapular, gluteal, and dorsal regions. Distal hind limb inflammation with thickened, fissuring skin and multiple sores was noted due to urine scalding. Respiratory rate was moderately elevated at 28 breaths per minute with normal respiratory effort. Other vital parameters were within reference intervals. Normal defecation was observed during examination, but the patient constantly dribbled urine without posturing to urinate. Blood was collected and submitted for a CBC and serum biochemistry panel. The following day, urine was collected via catheterization and was submitted for urinalysis. Polydipsia was supported by observing excess water drinking on admission. Once renal parameters were known, water was rationed rather than provided ad libitum.

#### **LABORATORY DATA:**

**Hemogram results: Sysmex XT-2000iV Hematology Analyzer**

TEST	FLAG	UNITS	RESULT	REFERENCE INTERVAL
<b>RBC</b>		$\times 10^{12}/L$	6.9	6.5 – 12.5
<b>HCT</b>		L/L	0.35	0.32 – 0.52
<b>HGB</b>		g/L	124	110 – 190

MCV		fL	52	34 – 58
MCH		pg	18	11 – 19
MCHC		g/L	350	310 – 370
PLTS		x 10 <sup>9</sup> /L	314	100 – 600
WBC		x 10 <sup>9</sup> /L	6.4	5.5 – 12.5
Neutrophils (Seg)		x 10 <sup>9</sup> /L	4.1	2.7 – 6.7
Bands		x 10 <sup>9</sup> /L	0.1	0.0 – 0.1
Basophils		x 10 <sup>9</sup> /L	0.06	0.0 – 0.17
Lymphocytes		x 10 <sup>9</sup> /L	1.6	1.5 – 5.5
Monocytes		x 10 <sup>9</sup> /L	0.5	0.0 – 0.8
Toxic change		-	Slight	-
Protein		g/L	76	60 – 77
Fibrinogen		g/L	3	< 5

**Biochemistry results: COBAS c501 Biochemistry Analyzer**

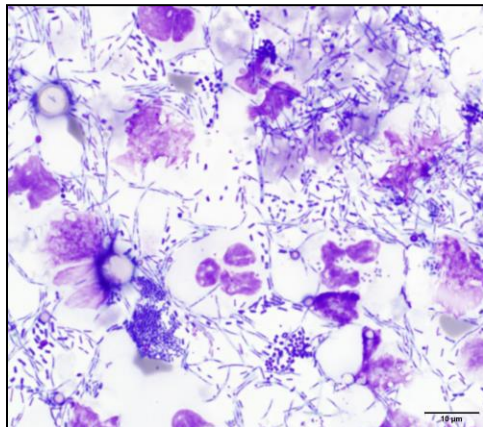
TEST	FLAG	UNITS	RESULT	REFERENCE INTERVAL
Sodium		mmol/L	138	135 – 148
Potassium		mmol/L	4.2	3.0 – 5.0
Chloride		mmol/L	101	98 – 110
Calcium		mmol/L	3.09	2.8 – 3.44
Phosphorus	L	mmol/L	0.8	1.0 – 1.8
Magnesium		mmol/L	0.83	0.74 – 1.02
Urea	L	mmol/L	2.3	3.5 – 7.0
Creatinine		μmol/L	122	78 – 143
Glucose	H	mmol/L	6.6	3.6 – 5.6
T. Bilirubin		mmol/L	10	4 – 102
ALP		U/L	204	95 – 233
GGT		U/L	12	0 – 25
SDH		U/L	6	1 – 15
AST		U/L	250	197 – 429
CK		U/L	278	50 – 500
T. Protein		g/L	75	60 – 77
Albumin	L	g/L	18	25 – 36
Globulins	H	g/L	57	24 – 44
A:G Ratio	L	-	0.32	0.60 – 1.50

**Urinalysis results: Collected via catheterization**

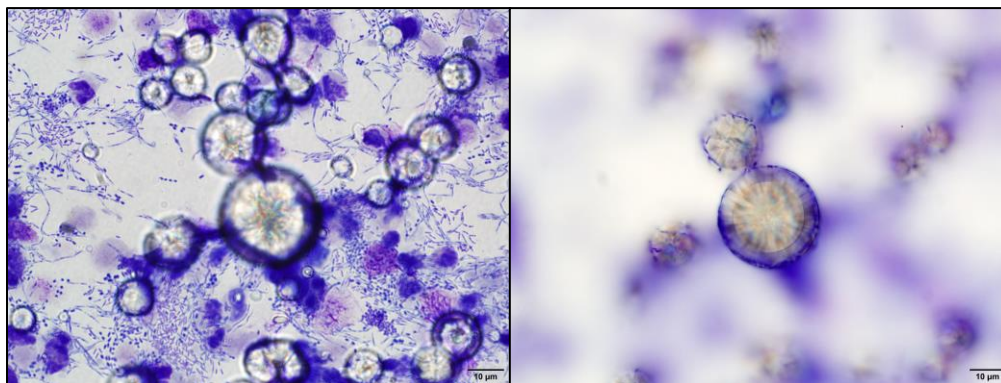
MACROSCOPIC TESTS	RESULT
Appearance	Yellow/Cloudy
USG	1.010
Protein	Trace
Glucose	Negative
Ketone	Negative
Blood	Trace
pH	7.5
Sulfosalicylic acid precipitation	1 g/L
Urobilinogen	1.7 $\mu\text{mol/L}$

MICROSCOPIC TESTS	RESULT
WBC/400x	TNTC
RBC/400x	6 – 10
Epithelial/400x	0
Crystals	++
Casts/100x	0
Bacteria	++++
Fat	–
Debris	–

**Images from Wright-Giemsa stained, smeared cytocentrifuged urine dry-mount are provided for evaluation.**



**Figure 1. Wright-Giemsa stained, smeared cytocentrifuged urine sediment**



**Figure 2. Wright-Giemsa stained, smeared cytocentrifuged urine sediment**

### **ADDITIONAL DIAGNOSTIC TESTS:**

Aerobic bacterial culture of urine resulted in multiple strains of *Escherichia coli* and a single *Enterococcus* species. Anaerobic bacterial culture of urine resulted in a single *Peptostreptococcus* species. The patient was unable to fully empty the urinary bladder through normal micturition, necessitating urinary catheterization and manual drainage. Approximately 9 liters of foul-smelling, brown turbid urine was obtained.

### **QUESTIONS:**

1. What is the most likely cause of crystal formation in this urine?
  - a. Inappropriately alkalotic urine
  - b. Clinically normal finding in horses
  - c. Hepatic injury or insufficiency
  - d. Artifact precipitation with delayed analysis
  
2. Which of the following is most likely to cause urinary incontinence as seen in this horse?
  - a. Neurologic dysfunction
  - b. Urinary obstruction
  - c. Urinary tract infection
  - d. All of the above