	GUIDE FOR DEVELOPING QUESTIONS FOR THE ECVCP EXAMINATION Document ID: 4	Document name: Guidance to prepare ECVCP exam questions v2	Page 1
		Date of last revision: 22/06/2017	Version 2

Author 1	Date: 22/05/2017	By: Laetitia Jaillardon (Examination Committee, Chair)
Controlled	Date: 01/06/2017	By: David Ledieu (Examination Committee)
Approved	Date: 22/06/2017	By: Cathy Trumel (Past-President)

A. FORMATTING GUIDELINES


Strict adherence to question formatting described below will greatly facilitate the ECVCP exam committee's task for editing questions and preparing the final exam typescript.

PLEASE ADHERE EXACTLY to the following format guidelines (See annexe 1). Use the New Times Roman 12 point font. Do not use indent or tab key functions or any customized formatting. Make sure that the Style is set on "Normal" and that all "outline", "automatic number lists", "automatic bulleted lists" and "heading" options are TURNED OFF.

1. Each question should be typed double-spaced on a single page.
2. At the top of each page, think the exam section and indicate any classification (**See annexe 2**).
3. Number of choice is restricted to **4 proposals**.
4. **Pyramidal questions are no longer acceptable**.
5. Label the choices letters A to D; there should be only **ONE** correct answer.
6. Arrange the choices in **increasing length** of the answer.
7. Indicate the correct answer either at the bottom of the page or by highlighting it in yellow. Write out the answer beside the letter.
8. Cite a complete reference including specific page numbers (see the official reading list reported in the esvcp/ecvcp website). The inclusion of a photocopy of the journal article or relevant page or pages from the source material would allow the ECVCP exam committee to more easily verify the question and citation.
9. Place your name as contributor at the bottom of the page.

B. CONSTRUCTION GUIDELINES FOR MULTIPLE CHOICE QUESTIONS

1. Most multiple choice questions are rejected because of construction or interpretability.

	GUIDE FOR DEVELOPING QUESTIONS FOR THE ECVCP EXAMINATION Document ID: 4	Document name: Guidance to prepare ECVCP exam questions v2	Page 2
		Date of last revision: 22/06/2017	Version 2

Often the subject material is desirable, but poor construction requires considerable labour in order to salvage the question, and these questions are discarded out of frustration.

2. Multiple choice questions for the ECVCP examination generally consist of a **brief stem** (introductory question) and **4 short responses** or "foils" (one correct and three distractors) **(See annexe 3)**.

Questions with more than one possible response can be submitted if properly formatted as ordering some statements that describe sequential steps of a pathophysiological mechanism for example.

The use of a picture from a textbook of the reading list is also possible (by asking which of a legend is appropriate for example). Please make sure that you are allowed to use it before.

3. The stem must be clearly formatted and stated as a question or incomplete statement. The problem to be solved should be stated **as clearly as possible** so that the candidates know what is being asked and what kind of response is expected. Someone who is knowledgeable about the subject should be able to answer the question without looking at the "foils". The following aspects should be considered:

a. Negative stems, long wordy stems, statements giving background information, and diffuse stems, should **preferably NOT be used**.

b. Stems are **preferably one line in length** and should not be more than two typed lines. Questions requiring data interpretation should be reasonable in the amount of data included (15 maximum). Remember, candidates have only a limited time to read and answer the question and find the correct answer. This is not an exam to test reading speed.

c. Avoid unfamiliar terminology. The difficulty must arise from the subject matter not from wording.


4. When writing foils, choose a correct answer that is indisputable and clearly identifiable from the reference. Make sure the distracters are incorrect, but plausible to candidates who do not know the answer. The number of questions with responses such as "All of the above", "None of the above", "Two of the above", will be limited.

a. **Foils are preferably only one line** or, at the most, two lines long.

b. The correct answer should not be noticeably longer or shorter than the distracters.

c. The foils should be **arranged from shortest to longest** in answers A to D, respectively.

e. Include as much information in the stem and as little in the options as possible.

	GUIDE FOR DEVELOPING QUESTIONS FOR THE ECVCP EXAMINATION Document ID: 4	Document name: Guidance to prepare ECVCP exam questions v2	Page 3
		Date of last revision: 22/06/2017	Version 2

- f. Avoid irrelevant clues to the correct option.
- g. Avoid complex, imprecise wording.
- i. Avoid alternatives that are synonymous with, include or overlap others.
- j. Avoid use of non-relevant sources of difficulty such as requiring a complex calculation when only knowledge of a principle is being tested.

C. GUIDELINES FOR PREPARATION OF VISUAL EXAM MATERIALS FOR HEMATOLOGY AND CYTOLOGY SECTIONS


The objective of visual materials should be to discriminate the experienced from the inexperienced clinical pathologist.

1. Glass Slides:


- a. Submit at least **5 copies of slides** of each proposed item.
- b. Slides should be **uniform** in composition. This is of particular concern for bone marrow aspirate films and cytologic preparations.
- c. Identify each slide with a slide number and name on a removable label.
- d. For each item submitted, include a written description and interpretation and a diagnosis with a differential when needed (**Annexe 4**).
- e. Please include your **recommendation for point distribution**.
- f. Include your name on the data sheet(s).

2. Kodachromes:

- a. **High quality JPG or TIFF images (min 300 dpi)** or interesting slide are used to construct a question/s aimed at (1) identification of a structure, (2) asking for a diagnosis or an interpretation and/or (3) additional questions based on morphology present on the slide.
- b. Glass slides or images regarding cytochemistry/immunocytochemistry are also appreciated: Submit a Romanovsky stained slide or **High quality JPG or TIFF images** together with the slide/image with the special stain.
- c. Submit a descriptive sheet (as for the glass slides) that includes a description of the key features to be recognized by candidates and the questions the submitter deems pertinent (**Annexe 5**).
- d. Up to 4 pictures might be used to illustrate a case (e.g. image of the blood tube, gross

	<p align="center">GUIDE FOR DEVELOPING QUESTIONS FOR THE ECVCP EXAMINATION</p> <p align="center">Document ID: 4</p>	Document name: Guidance to prepare ECVCP exam questions v2	Page 4
		Date of last revision: 22/06/2017	Version 2

appearance of the glass slide, low magnification, high magnification for details, etc...) They should be of high quality because they will be projected on a screen to the resident. Identify the written submissions and label each slide with your name.

	GUIDE FOR DEVELOPING QUESTIONS FOR THE ECVCP EXAMINATION Document ID: 4	Document name: Guidance to prepare ECVCP exam questions v2	Page 5
		Date of last revision: 22/06/2017	Version 2

Annexe 1

MULTIPLE CHOICE SUBMISSION FORM FOR THE SECTION OF:

- Please, tick one: GEN. CLIN. PATH./BIOCHEMISTRY/HEMATOLOGY/CYTOLOGY

- Classification:

- Species:

- Type of question (please, select one):

- Single correct answer type
- Sequential arrangements
- Interpretive question

- Stem of the question:

- Foils:

- A
- B
- C
- D


- Correct answer:

- Reference:

- Contributor's Name:

Section Leader's Evaluation and Comments (Leave Blank)

In _____ Out _____ Hold _____

	GUIDE FOR DEVELOPING QUESTIONS FOR THE ECVCP EXAMINATION Document ID: 4	Document name: Guidance to prepare ECVCP exam questions v2	Page 6
		Date of last revision: 22/06/2017	Version 2

MCQ no. 1: Haematology

Classification: Species specific hematology : Exotic / Leukocytes / Book

Stem of the question: **Which of the following proposal are TRUE about Guinea pig leukocytes?**

Foils:

A- Kurloff bodies stain positive with toluidine blue and PAS

B- Macrophages containing Kurloff bodies are like lupus cells in dogs

C- Large lymphocytes of guinea pig often contain a black inclusion referred as a Kurloff body

D- Eosinophils of the guinea pig are really easy to differentiate from other leukocyte as no heterophils are present in that species

Correct answer: 2

Reference: Campbell TW (2015): Exotic Animal Hematology and Cytology, 4th edition, Wiley Pp 124-127


Contributor's name: Eve Ramery

Section Leader's Evaluation and Comments:

In _____

Out _____

Hold _____

	GUIDE FOR DEVELOPING QUESTIONS FOR THE ECVCP EXAMINATION Document ID: 4	Document name: Guidance to prepare ECVCP exam questions v2	Page 7
		Date of last revision: 22/06/2017	Version 2

Annexe 2

EXAMPLES OF CATEGORIES FOR QUESTION CLASSIFICATION

Section of General clinical Pathology

Pathophysiology


- Systematic Pathology
- Urinary System
- Water + E-lytes
- Endocrine System
- Metabolic Diseases
- Immune System
- Hemolymphatic
- Digestive Tract
- MusculoskelSystem
- Skin
- Infectious Diseases
- Toxicology

Lab. Management

- Principles of test interpretation
- Method evaluation
- Quality control
- Reference interval

Section of Clinical Biochemistry

- Analytical techniques and instrumentation
- Enzymology
- Urinary System
- Proteins
- Monovalent electrolytes water balance, acid base disturbances
- Calcium, Phosphorous, Magnesium and their regulatory hormones
- Liver Function
- Carbohydrate Metabolism
- Exocrine Pancreas and Intestines
- Lipids
- Thyroid function
- Adrenocortical function
- Skeletal muscle


	GUIDE FOR DEVELOPING QUESTIONS FOR THE ECVCP EXAMINATION Document ID: 4	Document name: Guidance to prepare ECVCP exam questions v2	Page 8
		Date of last revision: 22/06/2017	Version 2

Section of Hematology

- Analytical techniques and instrumentation
- Erythrocytes
- Leukocytes
- Platelets
- Bone Marrow
- Hemostasis
- Neoplasia
- Immunohematology
- Species specific hematology

Section of Cytology

- Technical aspects
- Principles of cytologic evaluation and interpretation
- Infectious Agents
- Inflammation
- Tumor
- Skin
- Lymph nodes, Spleen
- CNS
- Head, Neck
- Fluids in body cavities
- Synovia, Musculoskeletal Syst.
- GI, Liver, Pancreas
- Urinary tract
- Respiratory tract
- Reproductive tract

	GUIDE FOR DEVELOPING QUESTIONS FOR THE ECVCP EXAMINATION Document ID: 4	Document name: Guidance to prepare ECVCP exam questions v2	Page 9
		Date of last revision: 22/06/2017	Version 2


Annexe 3

EXAMPLES OF MULTIPLE-CHOICE QUESTIONS FOR THE ECVCP EXAMINATION (from the ACVP SOPs)

Single correct answer type (* correct answer):

Stem of the question: **All the following sentences regarding serum fructosamine in cats are correct, EXCEPT:**

- A- Serum fructosamine concentration is increased in obese cats
- B- Serum fructosamine concentration is decreased in cases of hypoproteinemia
- C- Serum fructosamine concentration is increased in cats with diabetes mellitus
- D- Serum fructosamine concentration is increased in cases of stress-induced hyperglycemia *

	GUIDE FOR DEVELOPING QUESTIONS FOR THE ECVCP EXAMINATION Document ID: 4	Document name: Guidance to prepare ECVCP exam questions v2	Page 10
		Date of last revision: 22/06/2017	Version 2


Interpretive question:

A 2-year old dog presenting with icterus and weight loss has the following laboratory results:

Analyte	Patient	Ref interval
Total bilirubin (mg/dl)	5.8	0.1-0.6
Alkaline phosphatase (IU/L)	2980	50-250
Alanine aminotransferase (IU/L)	890	20-100
Gamma-Glutamyl transferase (IU/L)	28	1-8
Serum bile acids (μ mol/L)	175	0-5
Cholesterol (mg/dl)	395	65-240

Which is the most likely diagnosis?

- A. Hypothyroidism
- B. Chronic active hepatitis
- C. Glucocorticoid hepatopathy
- D. Extrahepatic bile duct obstruction*

	GUIDE FOR DEVELOPING QUESTIONS FOR THE ECVCP EXAMINATION Document ID: 4	Document name: Guidance to prepare ECVCP exam questions v2	Page 11
		Date of last revision: 22/06/2017	Version 2

Annexe 4

GLASS SLIDE SUBMISSION FORM FOR THE SECTION OF:

Please, tick one: HEMATOLOGY/ CYTOLOGY

Classification:

Case number:

Number of copies:

Specimen and stain:

Case description:

Morphologic description:

Interpretation: (include differential diagnoses and additional tests that should be performed)

Suggested keywords and points:


Contributor's Name:

Section Leader's Evaluation and Comments (Leave Blank)

In _____

Out _____

Hold _____

	GUIDE FOR DEVELOPING QUESTIONS FOR THE ECVCP EXAMINATION Document ID: 4	Document name: Guidance to prepare ECVCP exam questions v2	Page 12
		Date of last revision: 22/06/2017	Version 2

Exemple of glass slide description : a 7 year old neutered horse presented for a chronic weight loss, edema of limb, and anemia.

CBC Results:

WBC: $20.05 \times 10^3 / \mu\text{L}$ (RI 5-10)

HCT: 19.8% (RI 30-50)

Blood smear:

-Red blood cells:

* Semi -quantitative analysis: mildly reduced (0.25)

* Morphologic analysis:

Some rouleaux (0.25)

Marked anisocytosis (0.25)

Some echinocytes (0.25), some ovalocytes/ovaloacanthocytes (0.25)

Very few metarubricytes

-White blood cells:

* Semi -quantitative analysis: moderately increased (0.25)

Differential count: 9% GNN, 0% band cells, 23% lymphocytes, 12% monocytes, 56% monomorphic abnormal blastic cells


* Morphologic analysis:

Some reactive monocytes and lymphocytes (hyperbasophilic, granular)

Some toxic neutrophils, few GNE and GNB

Presence of an abundant and monomorphic population of blastic cells (0.25) (0.25): large size, moderate to high NCR, moderate clear basophilic cytoplasm containing sometimes some clear vacuoles or azurophilic granulations (0.25), a round to irregular nucleus (0.25) with a finely coarsed or abnormally clumped chromatin sometimes associated with 1 or 2 nucleoli (0.25).

-Platelets:

	GUIDE FOR DEVELOPING QUESTIONS FOR THE ECVCP EXAMINATION Document ID: 4	Document name: Guidance to prepare ECVCP exam questions v2	Page 13
		Date of last revision: 22/06/2017	Version 2

* Semi -quantitative analysis: very few platelets and platelet clumps (0.25)

* Morphologic analysis: no abnormality

Conclusion

Normocytic normochromic non-regenerative anemia (0.25) associated with a quite marked poikilocytosis

Marked thrombocytopenia (0.25)

Leukocytosis (0.25) associated with a slight neutropenia, a monocytosis and an abnormal abundant monomorphic blastic cells which could be from myelo-monocytic origin (AML 4/5) as 1st hypothesis (0.25).


➔ Suggestive of a possible myeloid leukemia (0.25), since no evident maturation is present (no bands, metamyelocytes, neutrophilia) (0.25)

Suggestions to improve or confirm the diagnosis:

-Cytology of bone marrow to trying to confirm a myeloid leukemia and try to subtype it (0.5)

-Flow cytometry (0.25) or immunohistochemistry/immunocytochemistry (0.25) on blood and/or bone marrow to confirm a myeloid leukemia (CD34 to confirm an acute leukemia, CD3-CD4-CD21-CD79a to exclude a lymphoid origin, and MPO (high in granulocytes and low in monocytes), NSA (granulocytes), CD14 and MAC387 (monocytes)...) to explore a myelo-monocytic origin and subtype the AML). Or cytochemistry (0.25) (peroxidase, phospholipid, chloracetate esterase, leukocyte alkaline phosphatase, alpha-naphtyl butyrate esterase (diffuse) to support a non-lymphoid origin, and chloracetate esterase - alpha-naphtyl butyrate esterase (diffuse) to support a myelomonocytic origin).

Total points: 5.5

	GUIDE FOR DEVELOPING QUESTIONS FOR THE ECVCP EXAMINATION Document ID: 4	Document name: Guidance to prepare ECVCP exam questions v2	Page 14
		Date of last revision: 22/06/2017	Version 2


Annexe 5

KODACHROME SUBMISSION FORM FOR THE SECTION OF:

- Please, tick one: HEMATOLOGY/ CYTOLOGY
- Classification:
- Case number (Indicate the name of the file or the identification label on the slide or print):
- Number of images:
- Species:
- Sample:
- Case description:
- Morphologic description (Outline of the morphologic changes, with reference to each image, in the case of multiple images):
- Morphologic diagnosis(es) (Interpretive summary of morphologic changes using appropriate terminology):
- Cause (List the cause(s) as specifically as possible):
- Other suggestions (Comment on whether any of the following would be appropriate for this case; e.g., name of disease, etiologic diagnosis, pathogenesis, special stains or other techniques used for diagnosis, associated clinical pathologic abnormalities, associated (primary or secondary) lesions in other tissues):
- Proposed examination question: List the question(s) you feel is (are) appropriate for the lesion(s) depicted (e.g., morphologic diagnosis(es), possible cause(s), name the disease, suggest a pathogenesis, differential diagnosis, commonly associated conditions, etc.). Be sure to include what you consider to be acceptable answers.
- References if necessary:
- Contributor's Name:

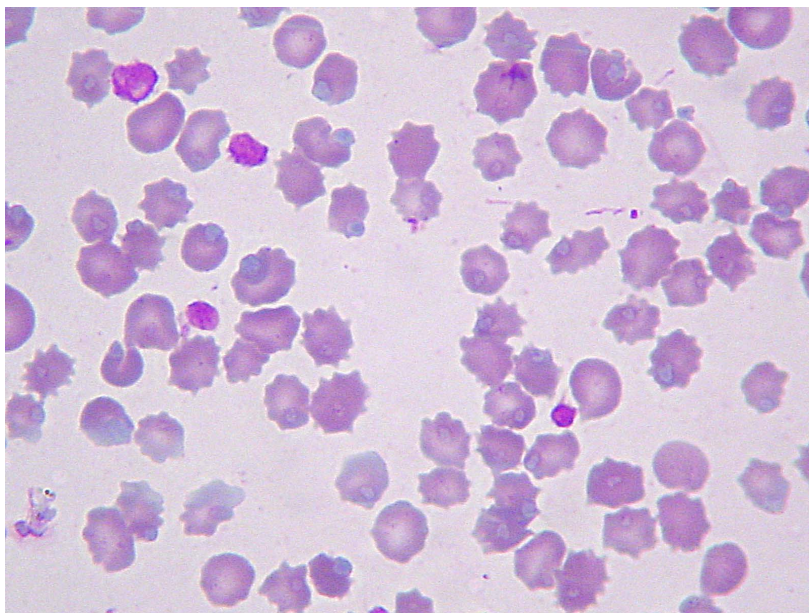
Section Leader's Evaluation and Comments (Leave Blank)

In _____ Out _____ Hold _____

	GUIDE FOR DEVELOPING QUESTIONS FOR THE ECVCP EXAMINATION Document ID: 4	Document name: Guidance to prepare ECVCP exam questions v2	Page 15
		Date of last revision: 22/06/2017	Version 2

Example of projected picture question : a 3 month-old DSH cat
 RBC count by ADVIA 2120

RBC	Result	Reference intervals	
RBC (x10 ⁶ /μL):	5.06	6	10.1
HGB (g/dL):	14.10	8,1	14,2
Cellular HGB (g/dL):	7.30	7,5	13,7
Hct (%):	21.60	27,7	46,8
MCV (fL):	42.60	41,3	52,6
MCH (pg):	27.80	12	16
MCHC (g/dL):	65.30	27	32,8
CHCM (g/dL):	33.90	26,9	33
CH (pg):	14.00	12	16
CHDW (pg):	3.07	1,6	2,7
RDW (%):	29.20	14,4	19,4
HDW (g/dL):	6.40	1,6	2,9
NRBC /100WBC:		0	0



Blood smear

Question (1 point): Based on the blood smear, how could you explain the discrepancy between Hgb and cellular Hgb? **Answer: Hemolysis (0.5 pt) and Heinz bodies (0.5pt)**