

Splenomegaly and hepatomegaly in a dog

Yvonne Wikander DVM^{1,2}, Susan Nelson DVM^{3,4}, Brandy Kastl DVM^{1,2}, Jonathon Sago DVM^{1,2}, Sarah Schneider DVM DACVP^{1,2}, William Vernau BSc, BVMS, DVSc, PhD⁵, Diana Schwartz DVM, DACVP^{1,2},

¹Department of Diagnostic Medicine/Pathobiology, Kansas State University College of Veterinary Medicine, Manhattan, KS

²Kansas State Veterinary Diagnostic Laboratory, Kansas State University, Manhattan, KS

³Department of Clinical Sciences, Kansas State University College of Veterinary Medicine

⁴Veterinary Health Center, Kansas State University, Manhattan, KS

⁵Department of Clinical Pathology, Microbiology & Immunology, University of California, Davis, CA

Phone: +1-503-858-7302

E-mail: ywikander@vet.k-state.edu

SIGNALMENT

10-year-old female spayed Border collie crossbred dog

HISTORY

Wilma presented to the Pet Health Center at Kansas State University for intermittent lethargy, cranial abdominal discomfort, and decreased appetite. Medications include prednisone every other day for previously diagnosed Systemic Lupus Erythematosus and atypical Addison's disease.

CLINICAL FINDINGS

Physical examination was largely unremarkable except for mild abdominal distention and discomfort on palpation. CBC, serum biochemistry panel, urinalysis, and bile acids were performed (results below). Abdominal radiographs and ultrasound demonstrated mild splenomegaly and hepatomegaly. Ultrasound-guided liver and splenic aspirates were obtained for cytology.

LABORATORY findings:

ANALYTE	UNITS	VALUE	REFERENCE INTERVAL
PCV	%	40	41-59
RBC	X 10 ⁹ /uL	5.25	5.8-8.2
Hgb	g/dL	13.1	14.1-20.5
MCV	fL	77.4	64-76
MCHC	g/dL	32.4	33-36
RDW	%	14.4	11.4-13.7
RETICULOCYTE	M/uL	0.09	0.01-0.12
RBC NOTES: Occasional polychromasia, occasional keratocytes, rare Howell-Jolly bodies			

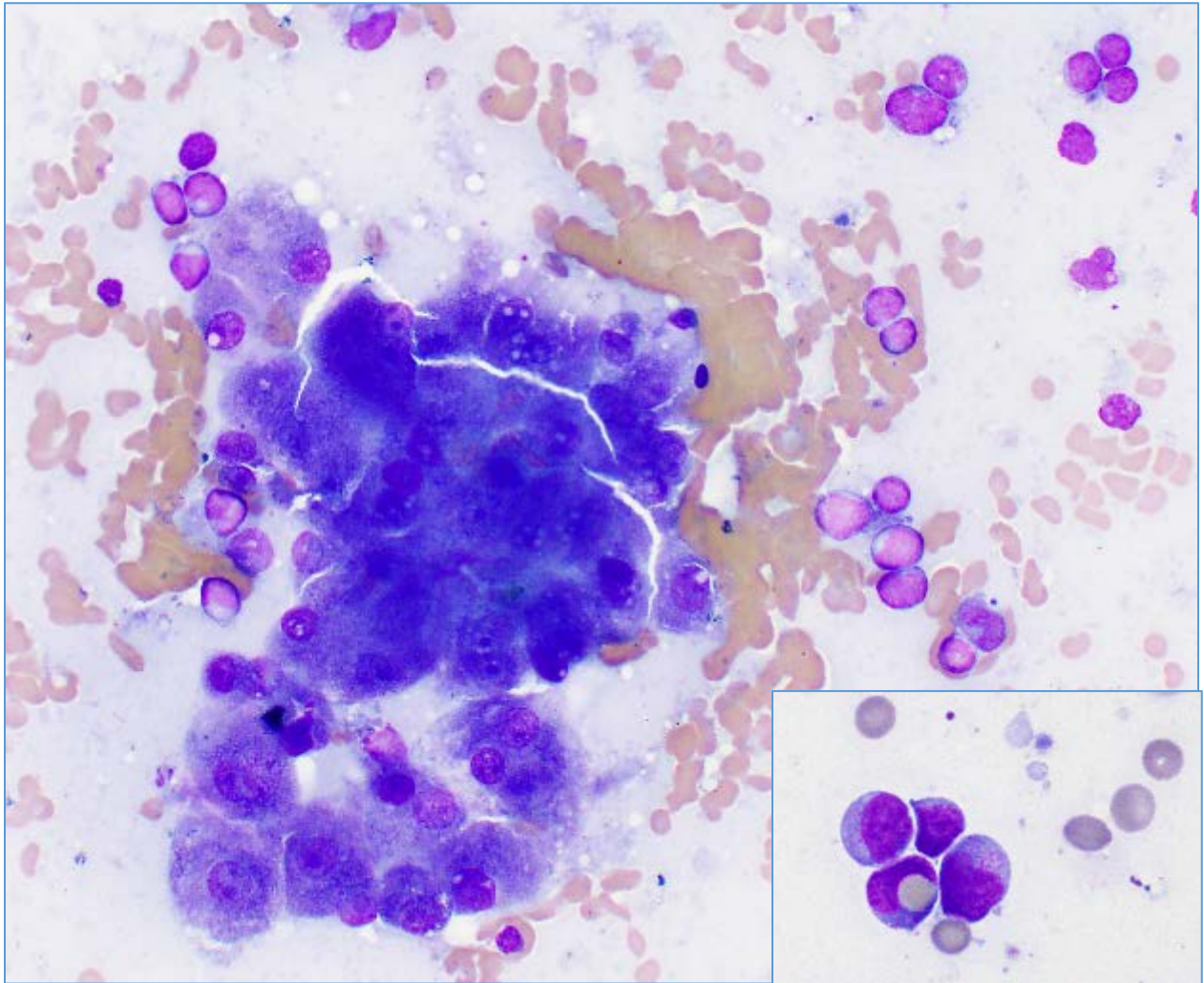
WBC	X 10 ³ /uL	10.0	4.3-13.6
NEUTROPHILS	X 10 ³ /uL	8.6	2.5-9.3
BANDS	X 10 ³ /uL	0	0-0.1
LYMPHOCYTES	X 10 ³ /uL	0.4	0.8-4.3
MONOCYTES	X 10 ³ /uL	0.8	0.1-0.9
EOSINOPHILS	X 10 ³ /uL	0.2	0-1.5
BASOPHILS	X 10 ³ /uL	0	0-0.1
PLT	X 10 ³ /uL	165	130-370
PLT NOTES: Clumps noted			
TP (refractometry)	g/dL	5.5	6.3-8.0

ANALYTE	UNITS	VALUE	REFERENCE INTERVAL
TOTAL PROTEIN	g/dL	4.4	5.3-6.9
ALBUMIN	g/dL	2.7	3.2-4.2
GLOBULIN	g/dL	1.7	1.8-3.0
UN	mg/dL	12	8-29
CREATININE	mg/dL	0.7	0.6-1.4
GLUCOSE	mg/dL	101	70-120
CHOLESTEROL	mg/dL	383	140-390
BILIRUBIN, TOTAL	mg/dL	0.7	0-0.2
ALT	U/L	923	20-144
ALP	U/L	621	10-130
CK	U/L	205	54-226
CALCIUM	mg/dL	8.5	9.5-11.2
PHOSPHORUS	mg/dL	4.5	2.2-6.1
SODIUM	mmol/L	150	144-151
CHLORIDE	mmol/L	117	106-117
POTASSIUM	mmol/L	4.7	3.7-5.0
HCO₃⁻	mmol/L	22	18-24
ANION GAP	mmol/L	17	18-27
SERUM NOTES: Icterus			
PT	Seconds	9.7	7-10
PTT	Seconds	14.7	9-15

ADDITIONAL TESTS

Bile Acids – Pre-prandial 11 $\mu\text{mol/L}$ (5-34); Post-prandial 48 $\mu\text{mol/L}$ (No RI)

LIVER ASPIRATE (Wright-Giemsa, 50x; inset 100x)

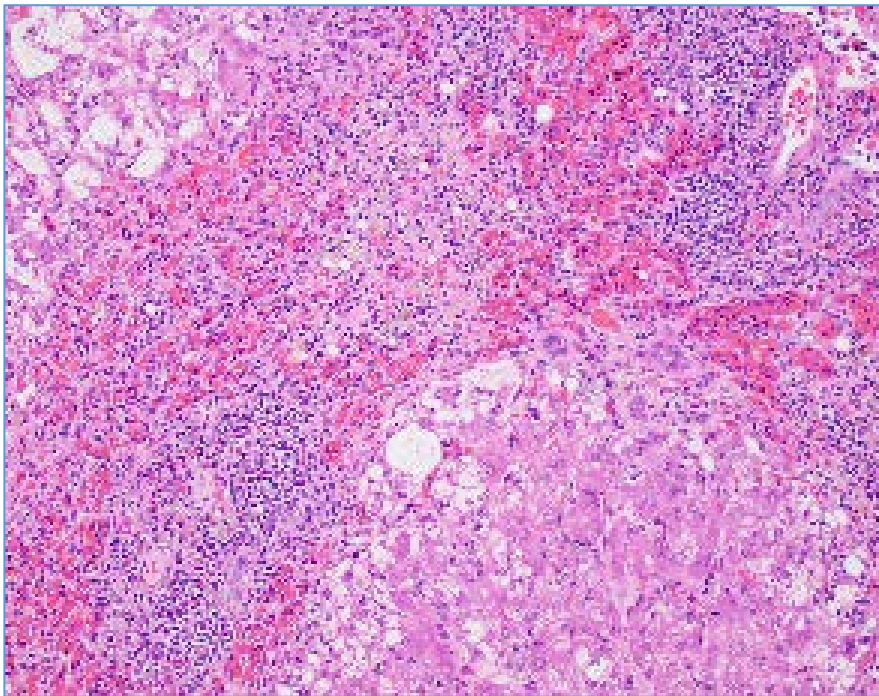


A similar lymphocytes were seen on the splenic aspirate.

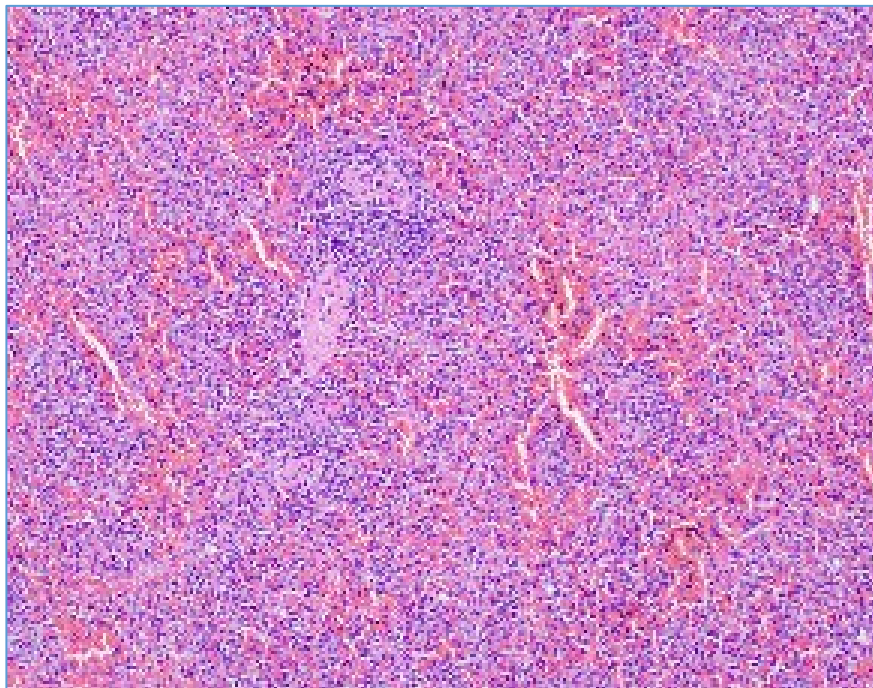
OUTCOME

The owner elected for palliative care and the patient was euthanized within a week due to her declining condition. The body was submitted for necropsy.

HEPATIC HISTOPATHOLOGY (H & E, 20x)



SPLENIC HISTOPATHOLOGY (H & E, 20x)



QUESTIONS:

1. Based on the cytomorphology and tissue distribution of lymphoid cells in this case, what immunophenotype(s) should be considered for these lymphoid cells?
2. What are reported primary locations for neoplasia of this lymphocyte type in veterinary species?