

CYTOLOGIC AND MOLECULAR DIAGNOSIS OF PERITONEAL CESTODIASIS IN A DOG

E. Piseddu¹, M. Trotta¹, L. Berlese², L. Solano Gallego³, G. Mezzalira¹, C. Masserdotti¹

¹Veterinary Diagnostic Laboratory and Hospital “San Marco”, Padua (Italy); ²Private Veterinary clinic “Madonna di Rosa”, Gorizia (Italy), ³Royal Veterinary College, London (UK).

Veterinary Diagnostic Laboratory and Hospital “San Marco”

Via Sorio 114/c

35141 Padova (Italia)

Tel. 00-39-049-8561098

Fax. 00-39-02 700 51 8888

E-mail: grifondoro@hotmail.com

Case Presentation with additional findings

A 10-year-old, mixed-breed male dog was presented to the referring veterinarians with a history of acute vomiting, anorexia and depression of three days of duration. The dog was adopted at 3-months of age in Sicily and moved to Gorizia (North-eastern Italy). At the time of clinical presentation, the dog lived alone indoor and outdoor. He was currently vaccinated and did not receive regular heartworm prevention treatment.

Physical examination revealed congested oral mucosal membranes, dehydration and abdominal distension with discomfort on abdominal palpation. An abdominal lateral radiograph revealed increased radio-opacity with a ground-glass appearance. Whole blood and serum samples were submitted for a CBC and chemistry panel by the referring veterinarian. The hematological parameters revealed a marked leucocytosis ($39.9 \times 10^9/L$, reference range $6-16 \times 10^9/L$), characterized by marked neutrophilia ($30.4 \times 10^9/L$, reference range $3-11.5 \times 10^9/L$) and moderate monocytosis ($5.6 \times 10^9/L$, reference range $0-1.5 \times 10^9/L$). Serum biochemical abnormalities included only mild hyperproteinemia (7.7 g/dL , reference range $5.7-7.1 \text{ g/dL}$) with normal A:G ratio. Other test results were within reference intervals. Abdominal ultrasound examination revealed marked ascites with hyperechoic particles; multiple cystic structures scattered on the peritoneal surface of the liver, spleen and omentum were observed. Exploratory abdominal surgery confirmed ascites and revealed multiple lobulated fluid-filled cysts and numerous yellow flecks of material were diffusely scattered on peritoneal surfaces of abdominal viscera. A sample of abdominal fluid was collected in a EDTA tube and submitted to Laboratory San Marco (Padua, Italy) for bacterial culture, fluid analysis and cytological evaluation. The abdominal fluid was medium pink to red in colour and moderately turbid. Numerous small flat white flacks approximately 3-5 mm in length were suspended throughout the fluid (Figures 1 and 2).

Culture was negative, and the fluid had a protein concentration of 5.0 g/dL , a specific gravity of 1.031, a total cell count of $54460/\mu\text{L}$, and a total nucleated cell count of $34460/\mu\text{L}$. Several unstained and May Grunwald-Giemsa-stained direct smears and a cytocentrifuged preparation of abdominal fluid were evaluated (Figures 3, 4, and 5). The background consisted of densely basophilic proteinaceous material that often formed crescents. A moderate number of non-degenerate

neutrophils were scattered throughout the slides. Low to moderate numbers of large, elongated, frequently distorted, intact or fragmented shaped organisms were observed. These organisms were composed of homogeneous pink to deep blue loosely arranged mesenchymal cells and a variable number of clear to yellow, round refractile spherules, compatible with calcareous corpuscles. A diagnosis of peritoneal cestodiasis, presumably caused by *Mesocestoides* sp., with secondary moderate neutrophilic inflammation was made. Molecular analysis to determine the *Mesocestoides* species was recommended.




Figure 1. Abdominal fluid from dog in an EDTA tube. Note the pink to red colour and moderate turbidity. Numerous opaque flecks of several millimetres in length are suspended throughout the fluid

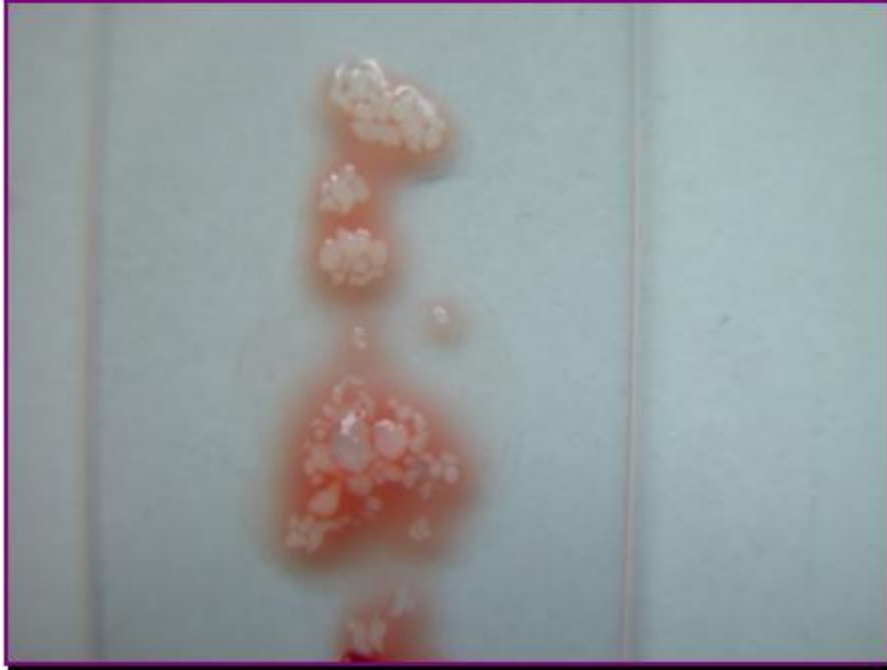

Figure 2. Gross appearance of abdominal fluid from dog, on a glass slide. Note numerous opaque flecks, approximately 3-4 mm suspended throughout fluid.



Figure 3. Direct smear of flecks suspended throughout fluid. Note numerous refractile calcareous corpuscles in the central region of the *Mesocestoides*. Unstained smear, 200x.

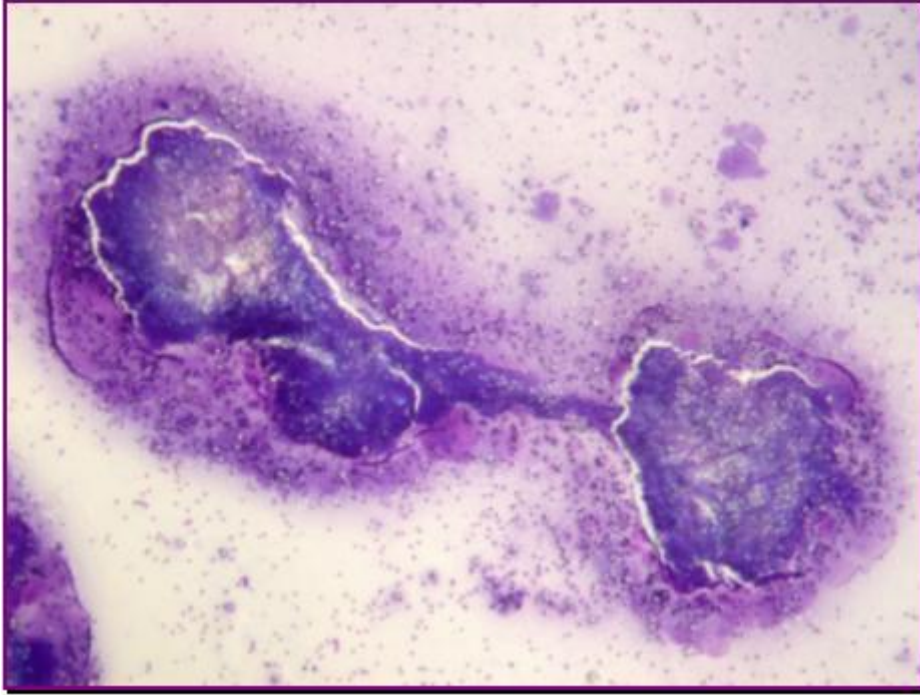


Figure 4. An elongated *Mesacestode* containing numerous calcareous corpuscles. May Grunwald - Giemsa in an automatic stainer (Aerospray slide stainer 7120, Wescor Delcon®), 100x.

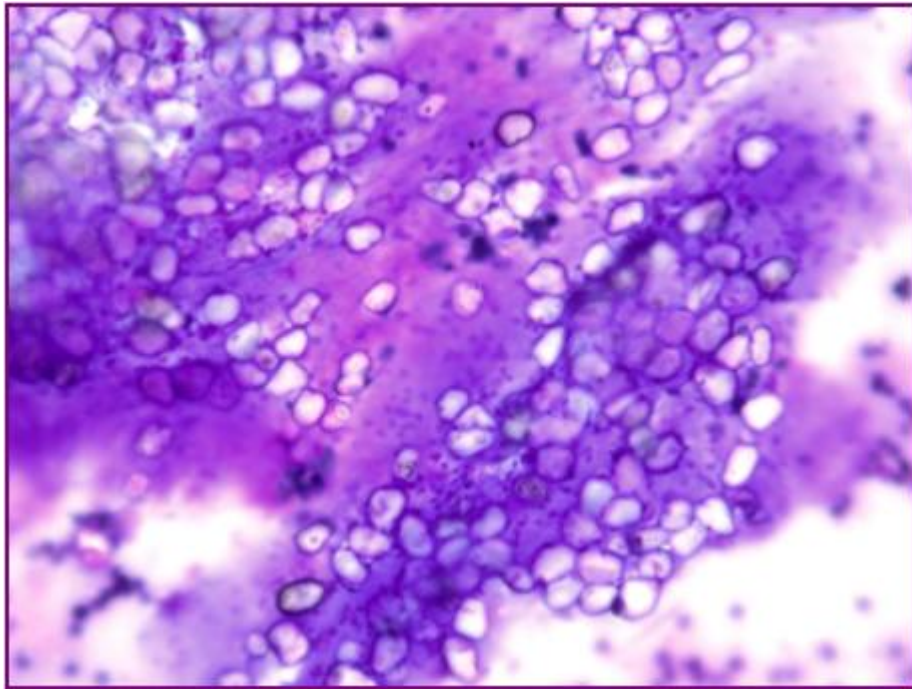


Figure 5. Numerous calcareous corpuscles, refractile structure characterized by concentric rings. May Grunwald-Giemsa in an automatic stainer (Aerospray slide stainer 7120, Wescor Delcon®), 500x.

The dog underwent a peritoneal lavage with saline isotonic solution in surgery. The resection of a colonic portion and anastomosis were performed due to the fact that the colon showed signs of occlusion, atypical structures and absence of motility,. Biopsy of the liver and the resected colon were submitted for histopathologic evaluation. Microscopically, the colon wall biopsies revealed a moderate and diffuse inflammatory process of lamina propria and muscularis mucosae composed mainly of eosinophils, lymphocytes and plasma cells. Crypts were characterized by frequent mitosis. Perivascular lymphoplasmacytic infiltrate was evident in the perivisceral adipose tissue and in the serosal surface of the colon. Mesothelial reactive hyperplasia and capillary neoangiogenesis were also observed (Figure 6). The serosal surface of the liver was demarcated by reactive mesothelial cells and multifocal to coalescent haemorrhages (Figure 7). Furthermore, a severe inflammatory process composed of neutrophils, plasma cells and lymphocytes was also noted in the serosal surface of the liver. Periportal and centrilobular haemorrhages with sinusoidal congestion were observed in the liver parenchyma. A moderate lymphoplasmacytic and neutrophilic infiltration in periportal areas was observed. Lipogranulomas were scattered among hepatocytes. A diagnosis of moderate eosinophilic chronic colitis, severe chronic peritonitis and diffuse mixed periportal hepatitis was made.

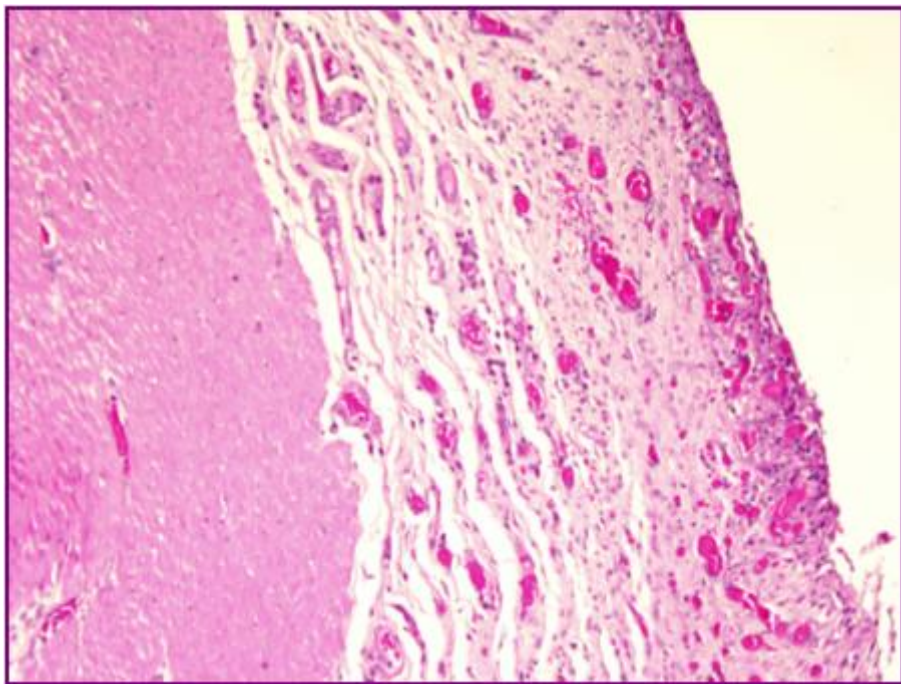


Figure 6. Reactive hyperplasia of mesothelium; notice the intense neoangiogenesis and the mild perivascular lymphoplasmacytic infiltrate. Haematoxylin-Eosin, 20X

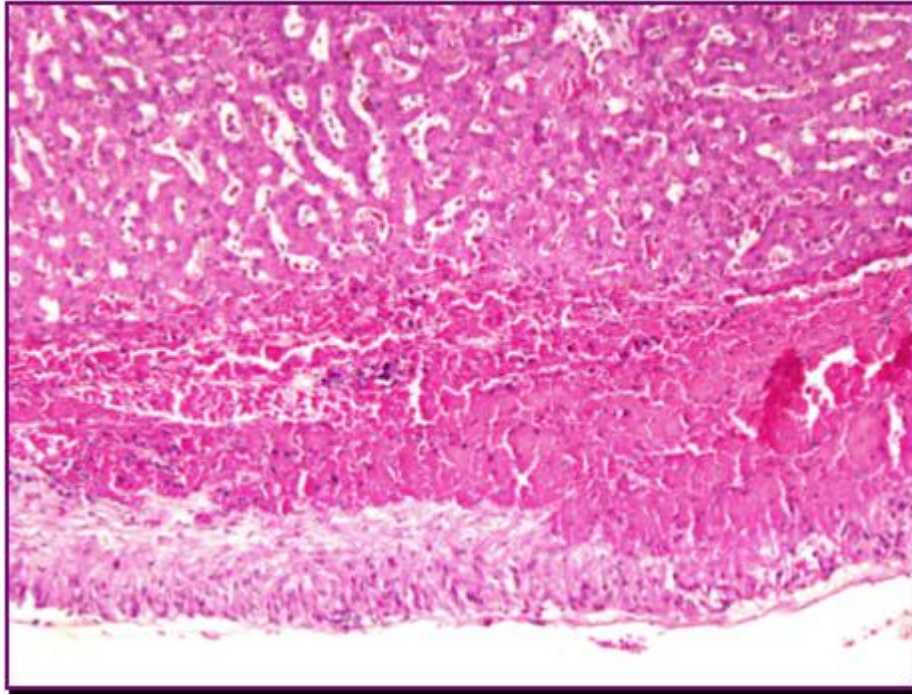


Figure 7. Intense reactive hyperplasia of glissonian mesothelium, with underlying haemorrhages. Haematoxylin-Eosin, 20X.

The cytological diagnosis was confirmed by molecular analysis of the abdominal effusion. Genomic DNA was extracted from abdominal fluid. An approximately 1,050 bp portion of DNA from the gene encoding for 18S rRNA was amplified in a conventional PCR reaction (Crosbie et al. 2000). The amplicon was directly sequenced, using ABI PRISM 3700 instrument, on both strands. The sequence obtained was compared with the *Mesocestoides* spp. sequences available in GenBank database. The sequence was aligned to the available sequences of *Mesocestoides* spp. and other representatives of class Cestoda. The sequence showed 99% identity with the 5 sequences available for *Mesocestoides corti*. Molecular testing was also performed on a fecal sample with a negative result in agreement with the negative result obtained by the referring veterinarian on fecal direct smear and flotation tests.

Treatment with enrofloxacin, amoxicillin and praziquantel were started after surgical procedures and cytological diagnosis. The dog improved and was sent home. Ten days later, the clinical condition of the dog was good, without sign of abdominal distension on physical examination. However, 20 days after surgery, the owner observed acute abdominal distension, anorexia and depression. Unfortunately, the dog died at home. Necropsy was done by referring veterinarian and histopathology of the spleen, stomach, abdominal wall and bladder was submitted to laboratory San Marco. A severe chronic peritonitis was diffusely present on all serosal surfaces: mesothelial cells were frequently arranged in papillary projections with a variable degree of mixed inflammatory infiltrates (Figure 8). Focally, on serosal surface, sporadic fragments of parasitic bodies (Figure 9), with superficial cuticle and many refractile spherules were observed. Spleen sections showed a diffuse hyperplasia of germinative follicles with moderate to severe sinusoidal congestion and many siderophages scattered among lymphoid cells.

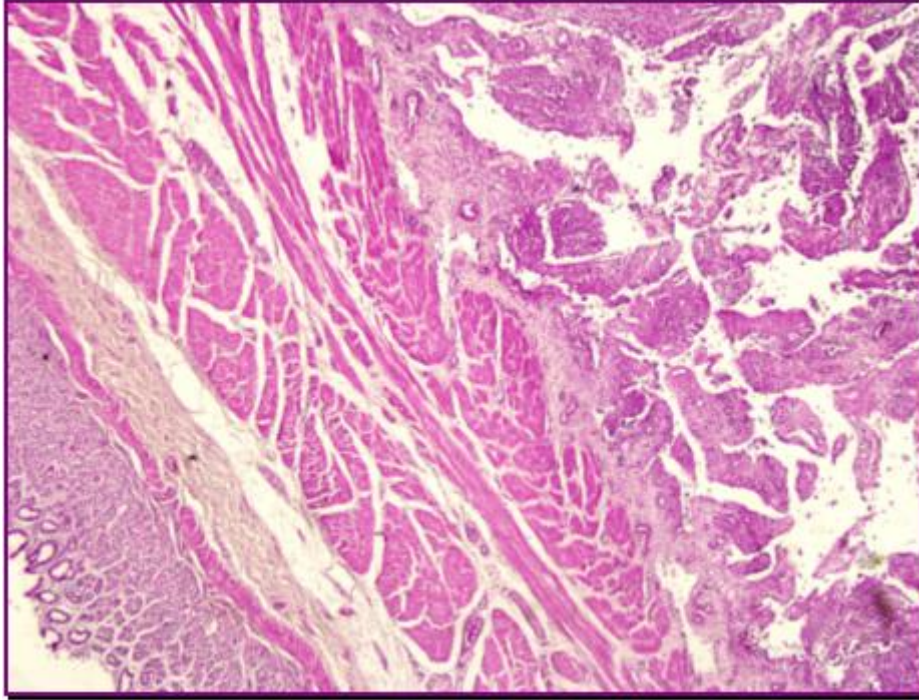


Figure 8. Severe chronic peritonitis on the serosal gastric surface, with multiple papillary projections. Haematoxylin-Eosin, 5X

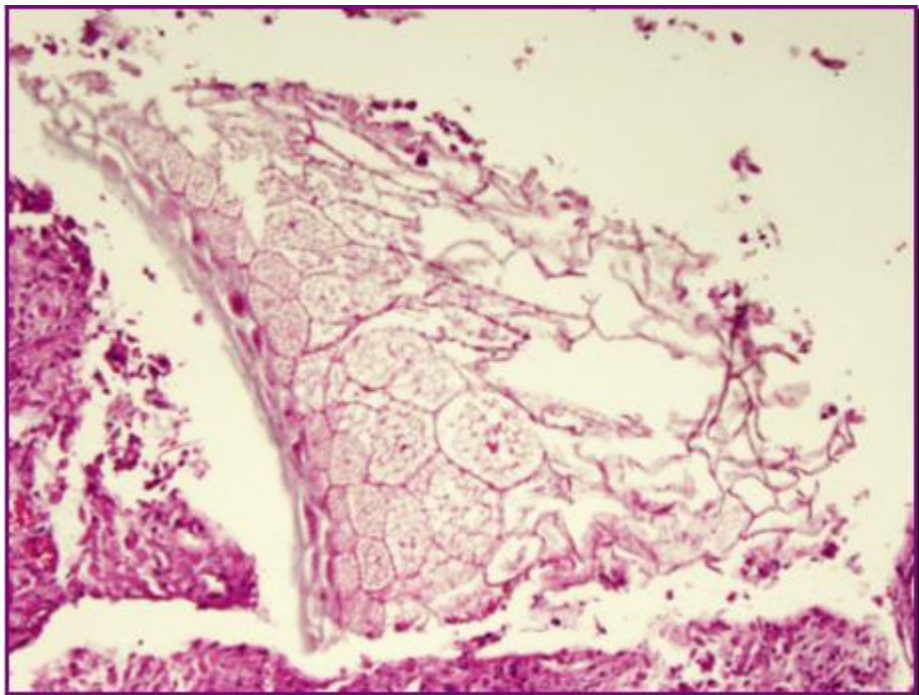


Figure 9. Serosal surface of the stomach. Notice the fragment of parasitic body with superficial cuticle and many refractile spherules. Haematoxylin-Eosin, 10x.

Discussion

Tapeworms of the genus *Mesocestoides* infect dogs, cats and wild carnivores in North America, Europe and Asia. The life cycle of *Mesocestoides* sp., is not completely understood, but two intermediate hosts and one final host are required. Initially, the eggs containing oncosphere (first larval stage) are ingested by a coprophagous arthropod and develops into cysticercoids (second

larval stage). The arthropod is ingested by a second intermediate host, such as reptiles, amphibians, birds, or small mammals in which the second larval stage develops into tetrathyridia (third larval stage). Tetrathyridia invade the peritoneal cavity and multiply asexually by budding or binary fission. These are then ingested by the final hosts and the parasite completes development within the intestine. Peritoneal infections can occur in both the second intermediate host and the definitive host, because ingested tetrathyridia can penetrate the intestinal wall. Dogs are usually considered a final host, but can also act as the second intermediate host. *Mesocestoides* infections occur mostly in dogs that engage in scavenging or predatory behaviour³. Peritoneal larval infection is likely under diagnosed, due to the fact that clinical manifestations vary from a subclinical infection to a severe disease in dogs. Clinical signs include abdominal enlargement, anorexia, vomiting, ascites and peritonitis as observed in the present case.

Hematologic findings are not specific for diagnosis, and usually include anemia, leukocytosis and occasionally monocytosis. The presence of neutrophilia and monocytosis in the present case is suggestive of chronic inflammation. Serum chemistry findings are often unremarkable in dogs with peritoneal cestodiasis, although hypoproteinemia has been commonly described previously^{1,2,5}. On the contrary, in the present case hyperproteinemia was observed and is most likely attributable to hemoconcentration or antigenic stimulation. The ultrasonographic features of the peritoneal larval infection were similar to those described by others, and consisted of marked ascites with hyperechoic particles and multiple cystic structures scattered on the peritoneal surface of several organs and peritoneal wall^{1,2,4,5}. The fluid obtained from abdomen was grossly similar and in agreement with previous reports. Several authors suggest that cytology is essential for in vivo diagnosis. In fact, the presence of organisms and calcareous corpuscles are pathognomonic for infection with a larval cestode. However, abdominal fluid analysis in dogs with *Mesocestoides* infection may be falsely negative when organisms become compartmentalized by either fibrinous adhesions or pyogranulomatous inflammation involving the surrounding tissue.

Fecal examinations are usually not useful for diagnosis. Negative fecal test results are typical in dogs with *Mesocestoides* larval infection, possibly indicating that ingestion of the first intermediate host is more common than ingestion of the second intermediate host². The molecular analysis is essential for the precise identification of *Mesocestoides* species³.

In the present case, the combination of cytology and molecular analysis allows identification of the species of mesocestoides. In the present case, the dog was infected with *Mesocestoides corti* a species previously described in Italy¹.

References

1. Bonfanti U, Bertazzolo W, Pagliaro L, Demarco B, Venco L, Casiraghi M, Bandi C. Clinical, cytological and molecular evidence of *Mesocestoides* sp. infection in a dog from Italy. *J Vet Med*, 2004. 51, 435-438.
2. Caruso KJ, James MP, Fisher D, Paulson RL, Christopher MM. Cytologic diagnosis of peritoneal cestodiasis in dogs caused by *Mesocestoides* sp. *J Vet Clin Path*, 2003. 32(2), 50-60.

3. Crosbie PR, Platzer EG, Nadler SA, Kerner C, Mariaux J, Boyce WM Molecular systematics of *Mesocestoides* spp (Cestoda: Mesocestoididae) from domestic dogs (*Canis familiaris*) and coyotes (*Canis latrans*). J. Parasitol. 2000. 82, 350-357.
4. Venco L, Kramer L, Pagliaro L, Genchi C. Ultrasonographic features of peritoneal cestodiasis caused by *Mesocestoides* sp. in a dog and in a cat. Vet Rad Ultr, 2005. 46(5), 417-422.
5. Wirtherle N, Wiemann A, Ottenjann M, Linzmann H, van der Grinten E, Kohn B, Gruber AD, Clausen P-H. First case of canine peritoneal larval cestodosis caused by *Mesocestoides lineatus* in Germany. Paras Int, 2007. 56, 317-320.