

# **Pulmonary Fine Needle Aspirate From a Cat**

## **Contributors**

**Martim C. Matias**,<sup>1</sup> Doroteia Bota,<sup>2</sup> Carolina Naranjo Freixa<sup>3</sup> Nazaré Pinto da Cunha<sup>4</sup>

<sup>1</sup>Veterinary Clinical Pathology Laboratory, Faculty of Veterinary Medicine, Lusófona University of Humanities and Technology, Lisbon, Portugal

<sup>2</sup>AniCura Restelo Veterinary Hospital, Lisbon, Portugal

<sup>3</sup>IDEXX Spain Laboratory, Barcelona, Spain

<sup>4</sup>Vedis, Porto, Portugal

Martim C. Matias – martim505@gmail.com

## **Specimen**

- Fine needle aspirate from lung nodular lesions
- Histopathology of lung fragment

## **Signalment**

8-year-old male castrated European Shorthair Cat

## **History**

An 8-year-old male castrated European Shorthair Cat presented for investigation of a 1-year history of progressive weight loss with recently increased respiratory rate and cough. The cat was not up-to-date vaccinated nor dewormed as he was a strictly indoor cat. For these complaints, he received antibiotics and steroidal anti-inflammatory drugs.

Complete blood count (CBC) and biochemistry had been performed and showed no major abnormalities.

## **Clinical findings**

Clinical examination revealed tachypnea and body condition score was slightly low (3/9).

Hematology and biochemistry results showed no major abnormalities. Total T4 was within normal limits.

Thoracic radiographs showed a multifocal alveolar pattern with areas of lung consolidation (Figure 1). Bronchoscopy showed irregular mucosa surface. Bronchoalveolar lavage was performed, and samples were submitted to another lab for cytologic examination and microbiological culture. Cytology results came back as “pyogranulomatous inflammation” but microbiology analysis was negative for both bacterial and fungal agents (Agar MacConkey, 37°C, Aerobic incubation, 48h; Blood, Agar, 37°C, Aerobic incubation, 48h; Agar Sabouraud chloramphenicol, 37°C, Aerobic conditions, 48h; Brain-Heart Infusion enrichment). Immunoglobulin measurements of anti-Toxoplasma IgG and IgM were within reference range.

The computed tomography scan displayed significant bilateral consolidations primarily located around the peri-hilar and peribronchovascular regions, with some exhibiting peripheral cavitation. Certain distal bronchi appeared tortuous, indicating the likelihood of associated atelectasis or anatomic distortion. Additionally, there were multifocal nodules primarily distributed along the peribronchovascular areas (Figure 2). The findings were suggestive of a chronic airspace disease with diffuse distribution. Immunoglobulin measurements of anti-Toxoplasma IgG and IgM were within reference range.

Oral and inhaled corticosteroid were used initially, which briefly improved the cat’s clinical condition, decreasing his respiratory rate and cough episodes for 2 months, after which hyporexia, weight loss and worsening of the lung pattern on thoracic radiographs was noted in a follow-up appointment. An ultrasound-guided fine needle aspiration of the lung was performed (Figure 3).

A tyrosine kinase inhibitor was introduced. Respiratory signs were milder over the following month, but weight loss and anorexia ensued and in the subsequent follow-up, an abrupt deterioration of the clinical condition was seen over the course of 1 week. Unfortunately, the cat died at home of respiratory insufficiency.

Lung samples were collected during necropsy, fixed in formalin and submitted for histopathological examination (Figure 4).

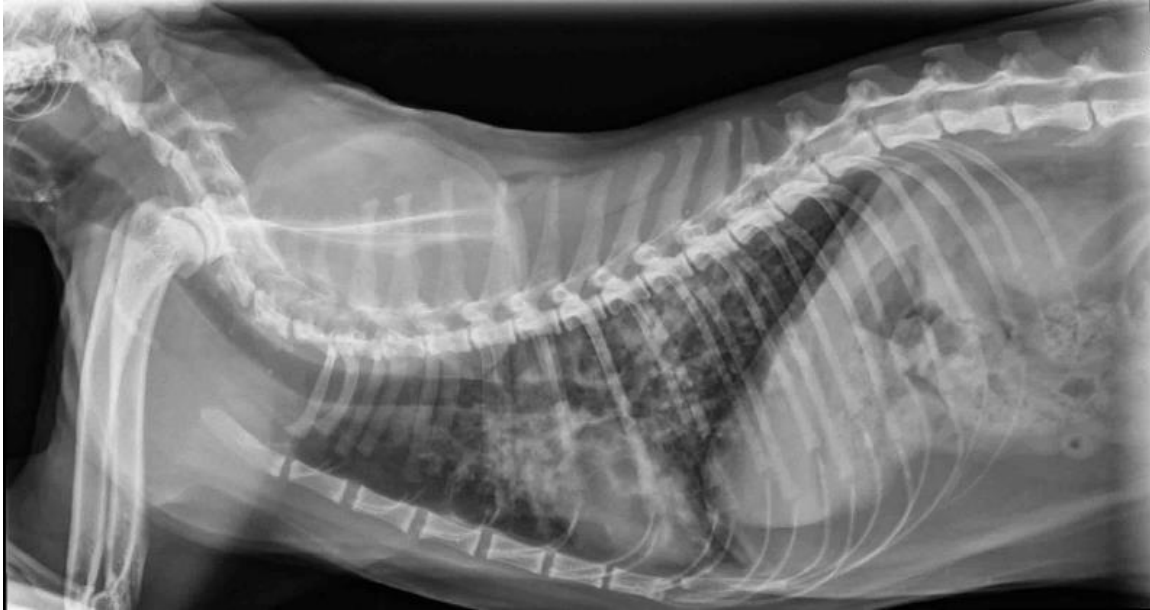

Figure 1. Left lateral thoracic radiograph from an 8-year-old male castrated European Shorthair cat at the time of presentation.

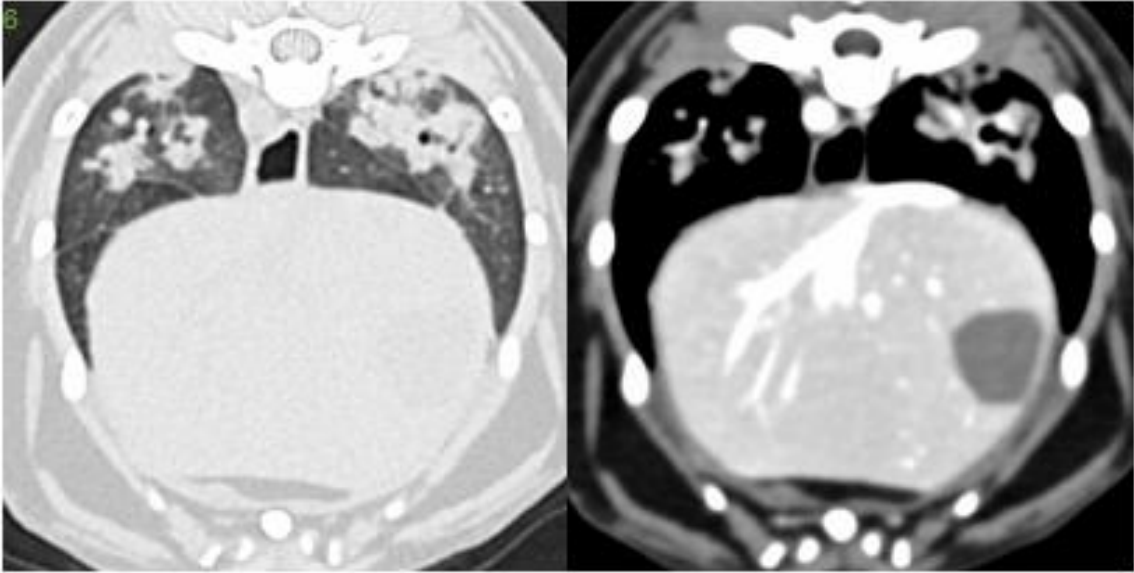
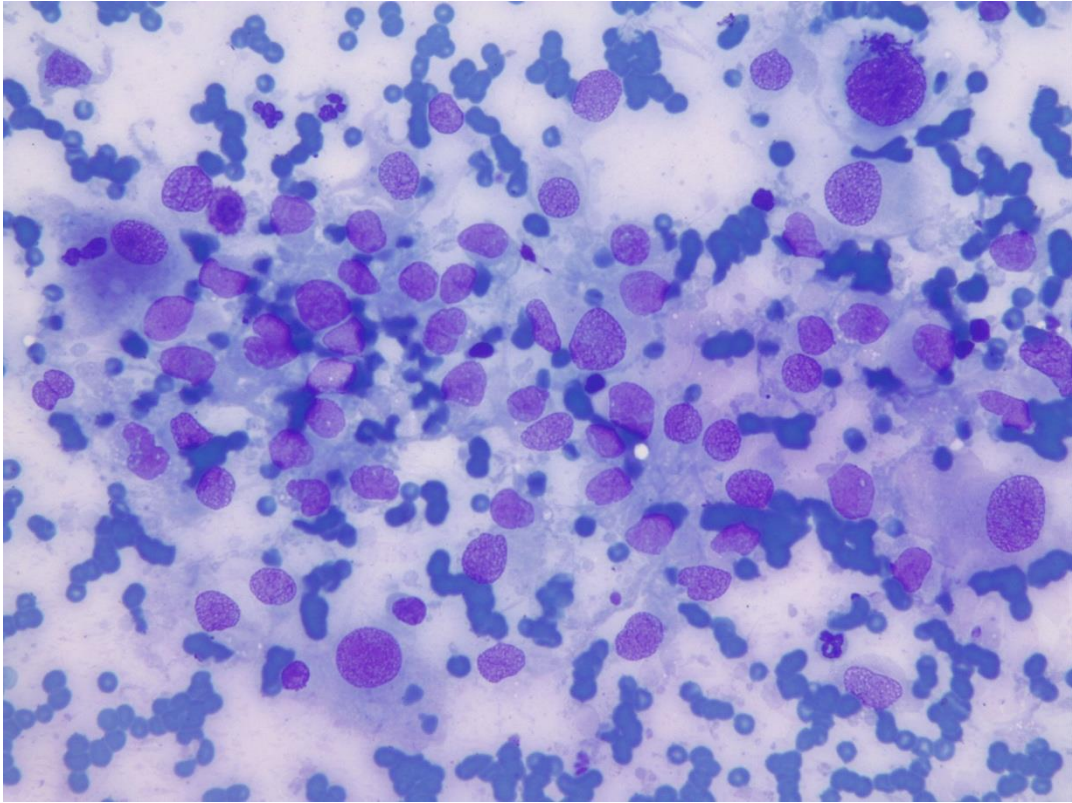


Figure 2. Computed Tomography from an 8-year-old male castrated European Shorthair cat.

A



B

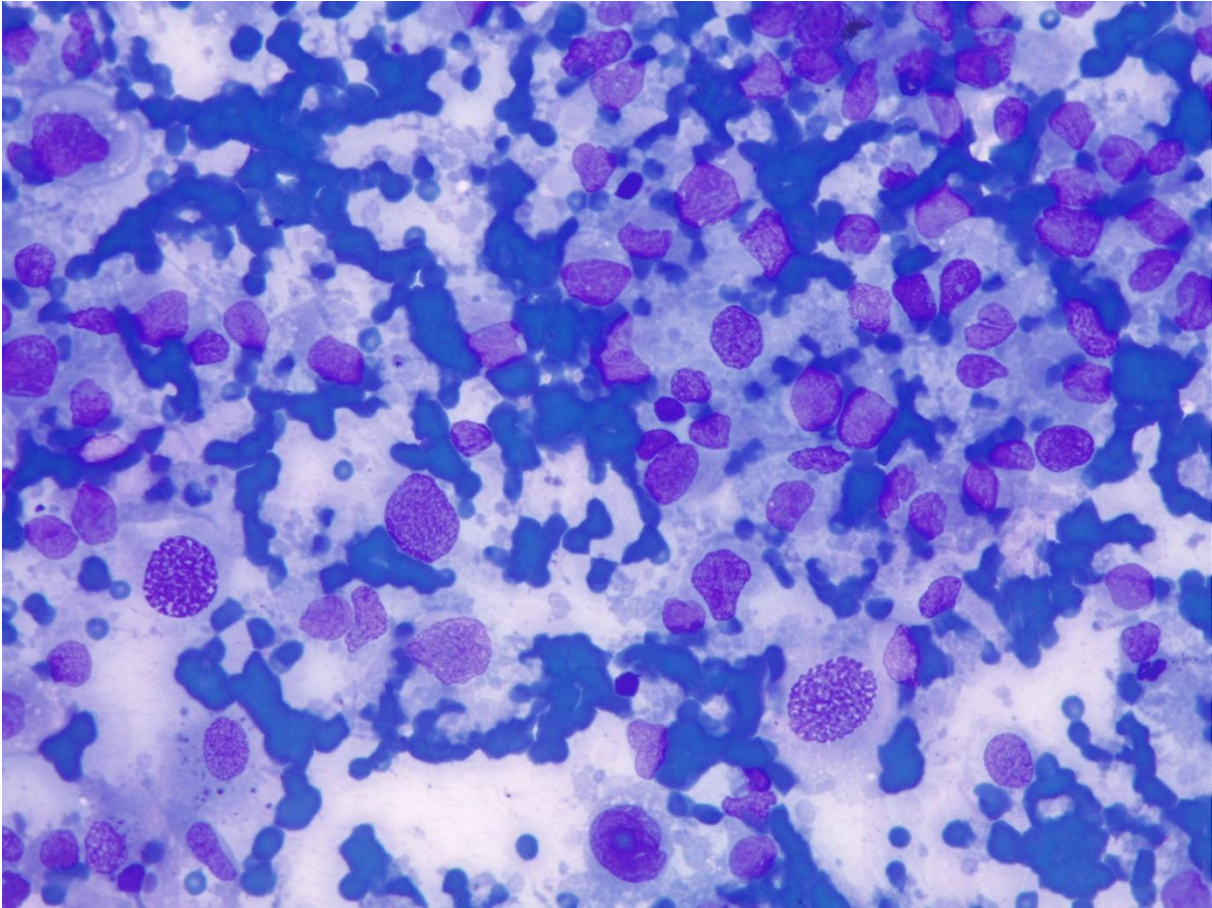
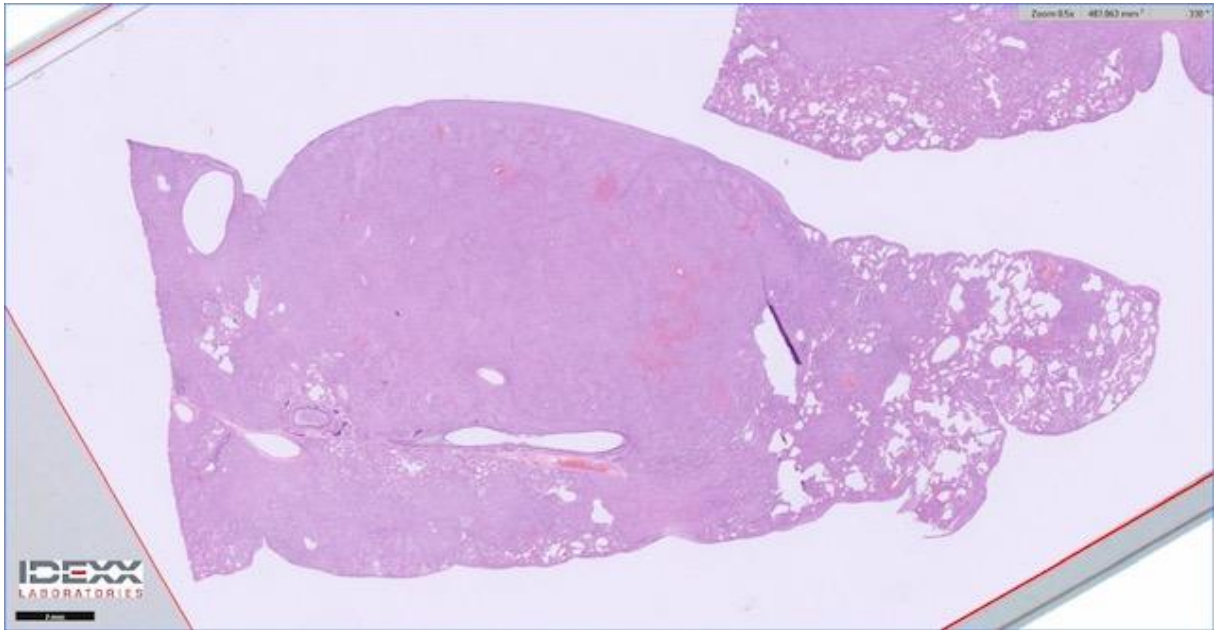


Figure 3, A, B Ultrasound-guided fine needle aspiration cytology of the lung of an 8-year-old male castrated European Shorthair cat. Diff-Quik stain. X40 magnification.

A



B

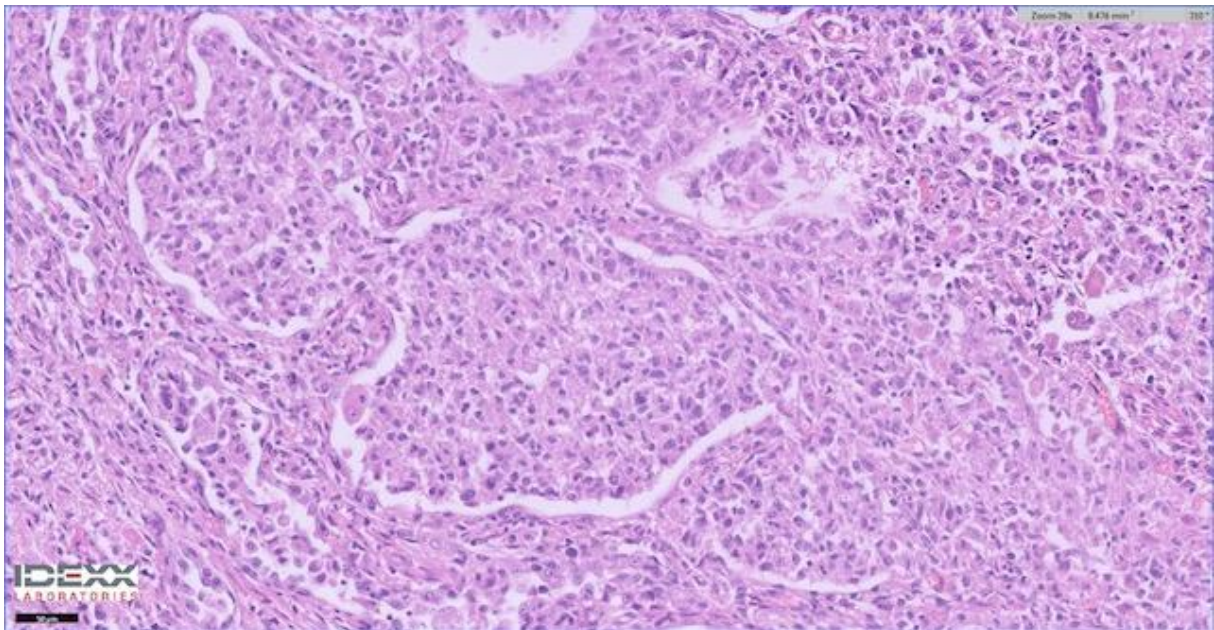


Figure 4. Histopathology sections of lung collected during necropsy of an 8-year-old male castrated European Shorthair cat. Hematoxylin and eosin stain. x0.5 magnification (A) and x20 magnification

(B).

## **Questions**

1. What is your description of the cytological findings?
2. Based on the clinical and pathological findings, what are your main differential diagnosis?
3. What additional tests would you use for confirming a diagnosis?