

## Case 11

### Dermic mass aspirate from a cat

M. Florenti <sup>1\*</sup>, G. Ghisleni <sup>2</sup>, M. Caniatti <sup>2</sup>.

<sup>1</sup> Private Veterinary Clinic “Gran Sasso”, Milan, Italy.

<sup>2</sup> Dipartimento di Patologia Animale, Igiene e Sanità Pubblica Veterinaria (DIPAV), Università degli Studi di Milano, Italy

\*Corresponding Author. E-mail Address: manuela.florenti@gmail.com

**Signalament:** A 4 years old tabby cat, castrate male.

#### Clinical Findings:

The cat was presented for evaluation of a cutaneous mass on the dorsal thorax. On presentation the cat was in good body condition. The results of clinical examination were unremarkable except for a 0.8 cm diameter, lobulated, not ulcerated skin thoracic mass. Results of a CBC and serum biochemistry were unremarkable.

Cytology samples, obtained by fine needle aspiration biopsy (FNAB), were air dried and stained with May-Grünwald-Giemsa (Figures 1, 2, 3 and 4).

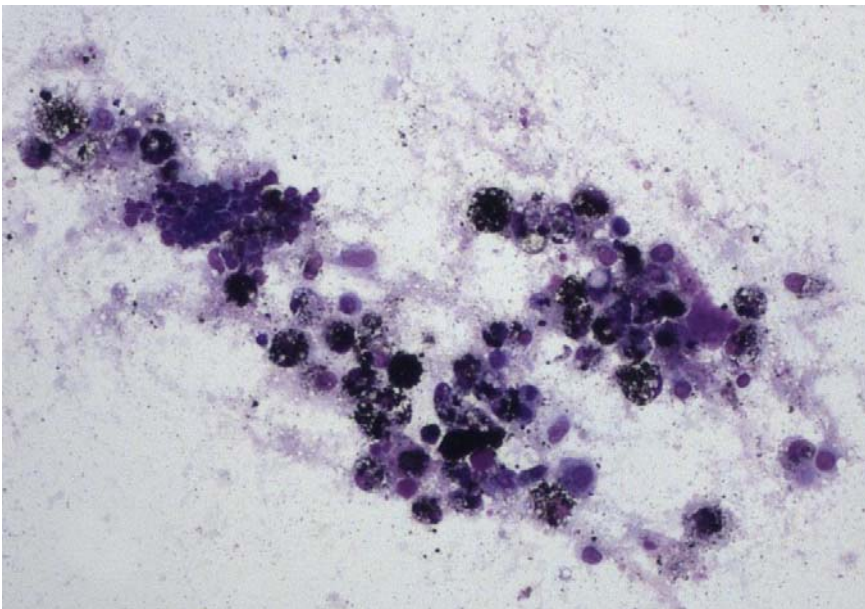


Figure. 1 FNA of a thoracic cutaneous mass of a cat. May-Grünwald Giemsa, 10x.

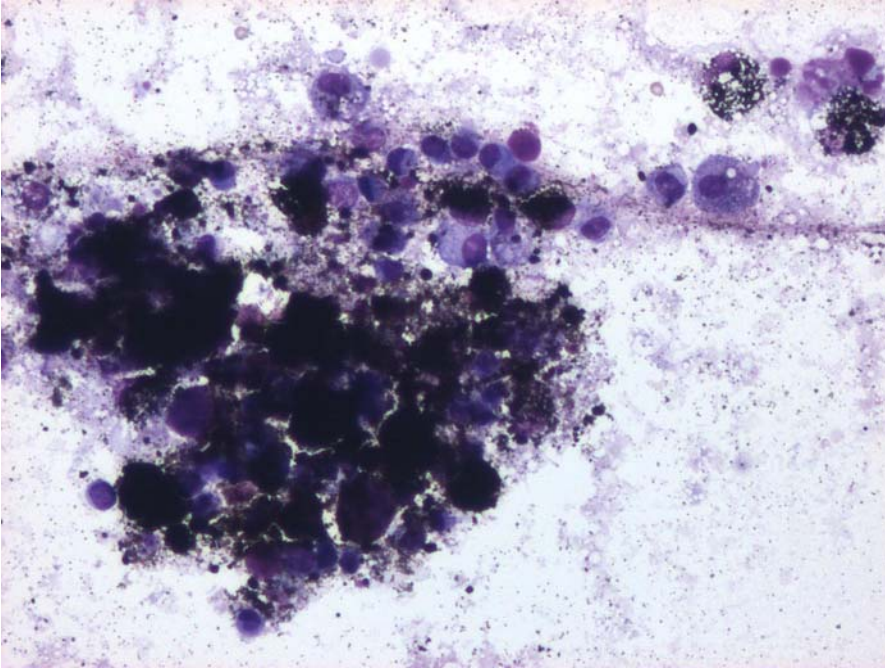


Figure. 2 FNA of a thoracic cutaneous mass of a cat. May-Grünwald Giemsa, 20x.

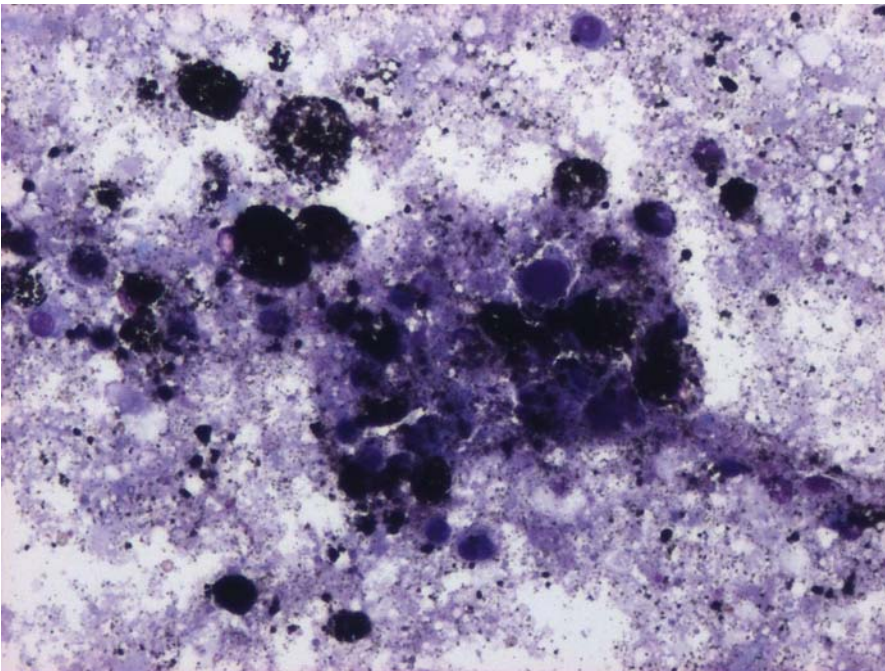


Figure. 3 FNA of a thoracic cutaneous mass of a cat. May-Grünwald Giemsa, 20x.

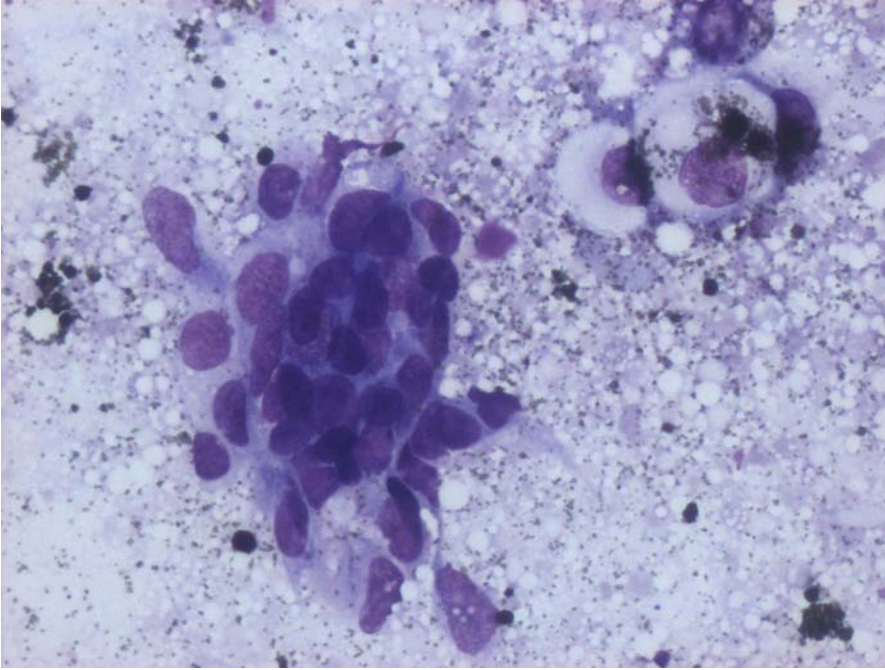


Figure. 4 FNA of a thoracic cutaneous mass of a cat. May-Grünwald-Giemsa, 40x.

The mass was surgically excised. Grossly, the mass was 0,8 cm in diameter and solid in texture. On cut section (Fig. 5), the mass was dermic and consisting of multiple, circumscribed, small black lobules with few white foci. The specimen was fixed in 10% buffered formalin for histopathologic examination.

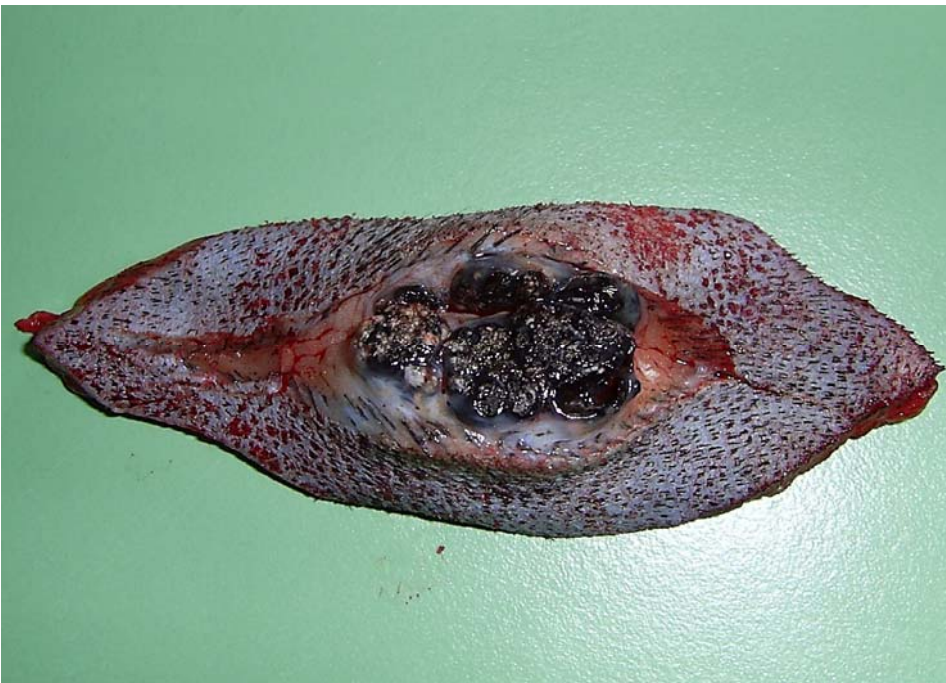

Figure 5. Cutaneous mass of a cat. Macroscopic appearance of cut section of the lesion.