

Disseminated Histoplasmosis in a Dog—Case Discussion

Contributors

Rebekah G. Gunn-Christie, DVM, DACVP*
Antech Diagnostics, Inc., Cary, North Carolina, USA

Sean Hillock, DVM, DACVIM (internal medicine)
Veterinary Medical Center of Long Island, West Islip, New York, USA

*Corresponding author: rebekah.gunn@antechmail.com

Figure 1: Peripheral blood smear feathered edge, 50X objective, Wright's-Giemsa stain. Numerous small, (~4 micrometer) round to oval organisms consistent with *Histoplasma capsulatum* yeasts. These structures have a narrow colorless halo and pale basophilic protoplasm with a purple nucleus. Yeast are noted within a macrophage as well as free in the background of the smear.

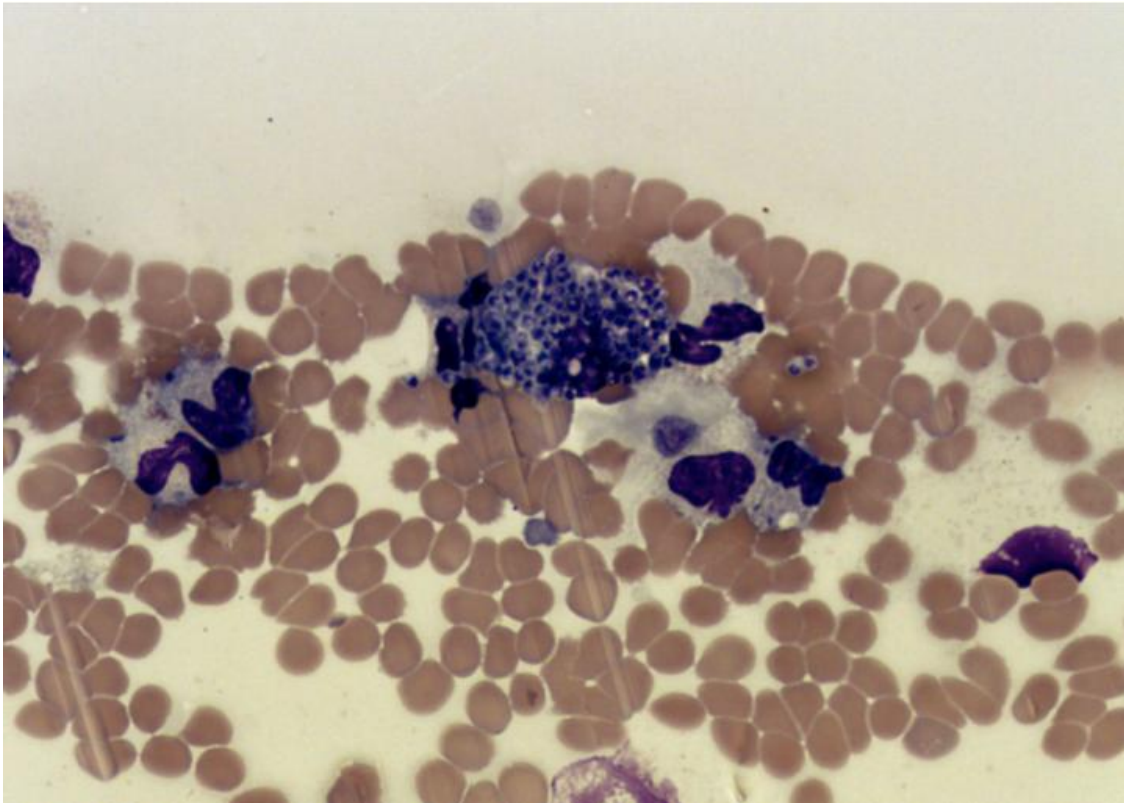


Figure 2: Peripheral blood smear, 100X objective, Wright's-Giemsa stain. A toxic neutrophil containing two *H. capsulatum* organisms. Additional yeast are also seen in the background. Note marked thrombocytopenia evident in this image.

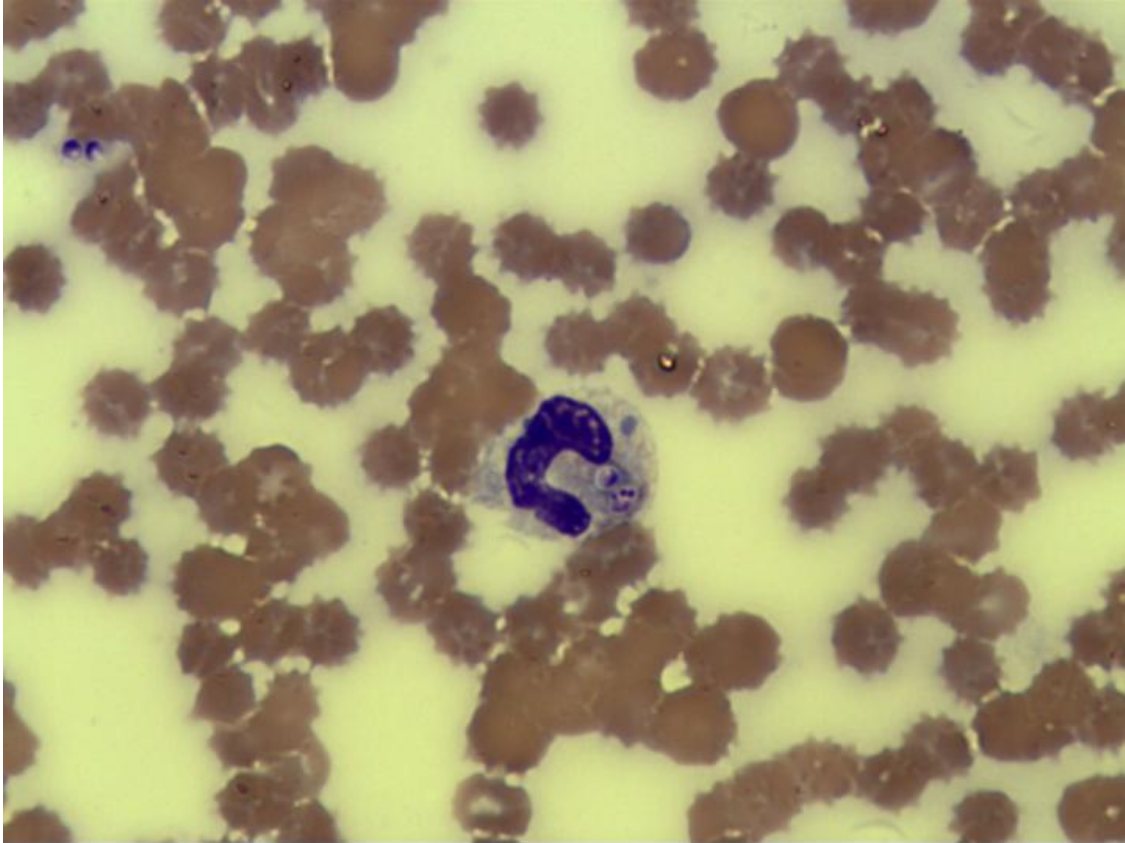


Figure 3: Peripheral blood smear feathered edge, 100X objective, Wright's-Giemsa stain. A macrophage laden with numerous *H. capsulatum* organisms is seen along the feathered edge of the smear.

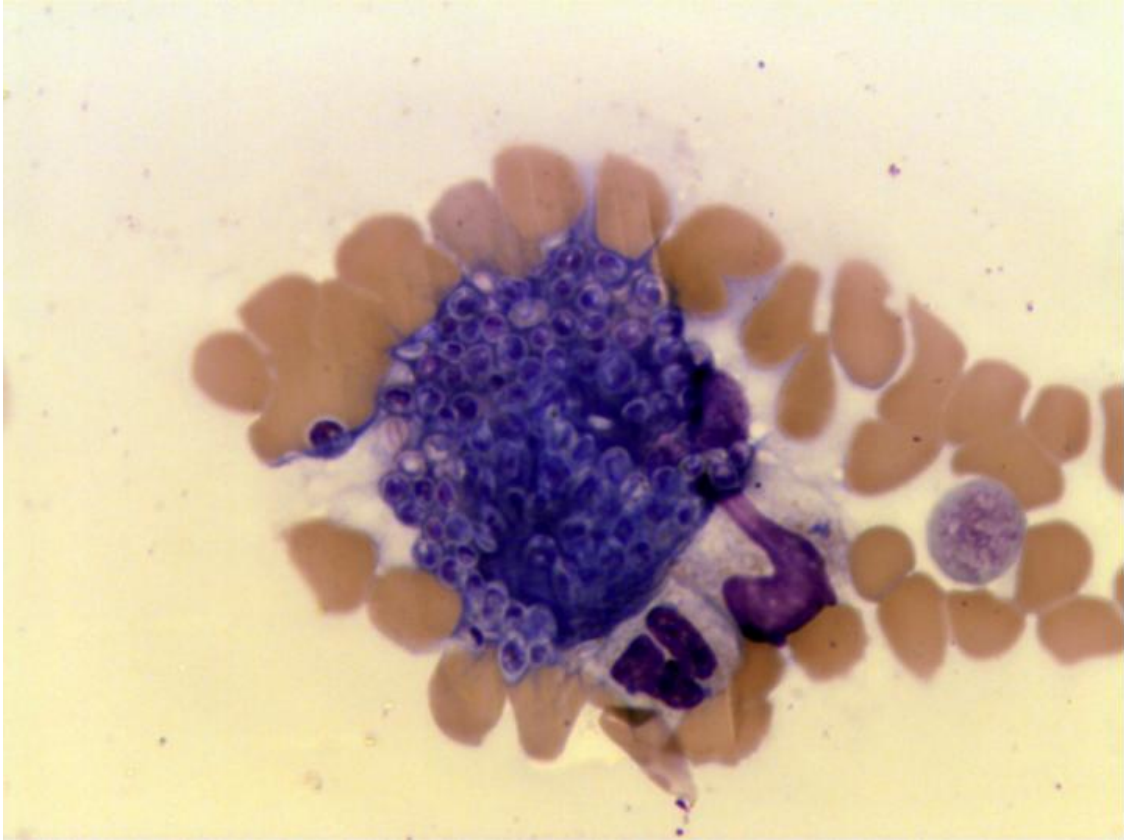
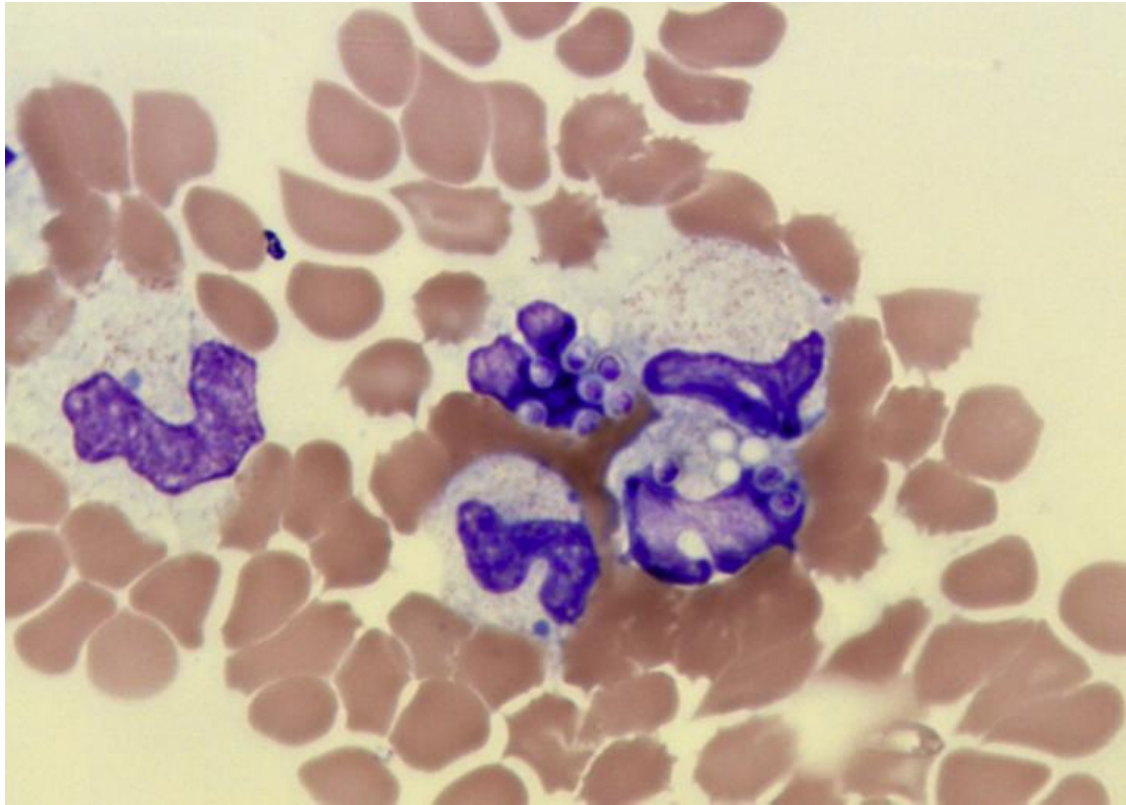


Figure 4: Peripheral blood smear, 100X objective, Wright's-Giemsa stain. A collection of neutrophils exhibiting toxicity and left shifting. *H. capsulatum* organisms are seen in some of the neutrophils.



Absolute neutrophil count is within the reference interval; however, a significant but regenerative left shift with moderate toxicity is present. Many neutrophils contain one to multiple small (~4 micrometer), round to oval yeast-like organisms. These structures have a narrow colorless halo and pale basophilic protoplasm with a purple nucleus. Occasional macrophages also contain numerous yeasts. Yeast organisms are also noted throughout the background of the smears. These yeast structures are consistent with *Histoplasma capsulatum* organisms and suggest this patient has disseminated histoplasmosis. Abdominal ultrasound with aspirates of abnormal findings, lymph node and bone marrow aspirates, and thoracic radiographs may be considered to help determine the extent of involvement. Clumps of platelets are seen, but they are fairly small and do not seem sufficient to account for the decreased number of platelets in the body of the smear. A thrombocytopenia is likely. Differential considerations include decreased production, increased destruction/consumption, and sequestration. Red cell density is mildly decreased with minimal evidence of regeneration; a normocytic, normochromic, presumably nonregenerative anemia is present. Given the patient's presumed histoplasmosis, anemia of inflammatory/chronic disease would be the most likely consideration. No neoplastic cells are seen.

Abdominal Ultrasound

Abdominal ultrasound revealed mottled splenomegaly, diffusely hyperechoic hepatomegaly, and moderate hypoechoic mesenteric lymphadenopathy (more than expected for a normal puppy). Remainder of the ultrasound was unremarkable; the gastrointestinal tract appeared normal; the bowel mucosa was determined to be within normal limits. A repeat CBC performed immediately prior to abdominal ultrasound and collection of aspirates revealed similar findings to the initial CBC with the exception that the platelet count was 220,000 per microliter. The automated platelet count was confirmed by visual inspection of a blood smear (the estimated platelet count was 150-200,000 per microliter). After determining that the patient was no longer thrombocytopenic and with no other evidence of hemorrhagic tendencies, aspirates of liver, spleen, and lymph node were collected and submitted for cytology.

Hepatic aspirate (Figures 5&6): The slides are of adequate staining and preservation of cellular detail with abundant hemodilution present against a pale basophilic background. A moderately cellular hepatic aspirate is present that contains hyperplastic hepatocytes individually and in small groups. These cells exhibit mild to moderate anisocytosis but mild anisokaryosis with a low but occasionally slightly increased nuclear:cytoplasmic ratio. They are oval to polygonal with distinct borders and abundant cytoplasm with increased basophilia. The nuclei are large, round, and centrally-placed with a coarse chromatin pattern and a single prominent nucleolus. A significant mixed inflammatory cell infiltrate consisting primarily of macrophages and neutrophils, many of which contain phagocytized *H. capsulatum* organisms. Additional *H. capsulatum* organisms are noted throughout the background as well as embedded within clusters of hepatocytes. No neoplastic cells are seen.

Figure 5: Hepatic aspirate, 100X objective, Wright's-Giemsa stain. A sheet of hyperplastic hepatocytes with markedly increased cytoplasmic basophilia. To the left, a neutrophil containing numerous *H. capsulatum* organisms is seen. Additional yeast are also seen in the background of the smear.

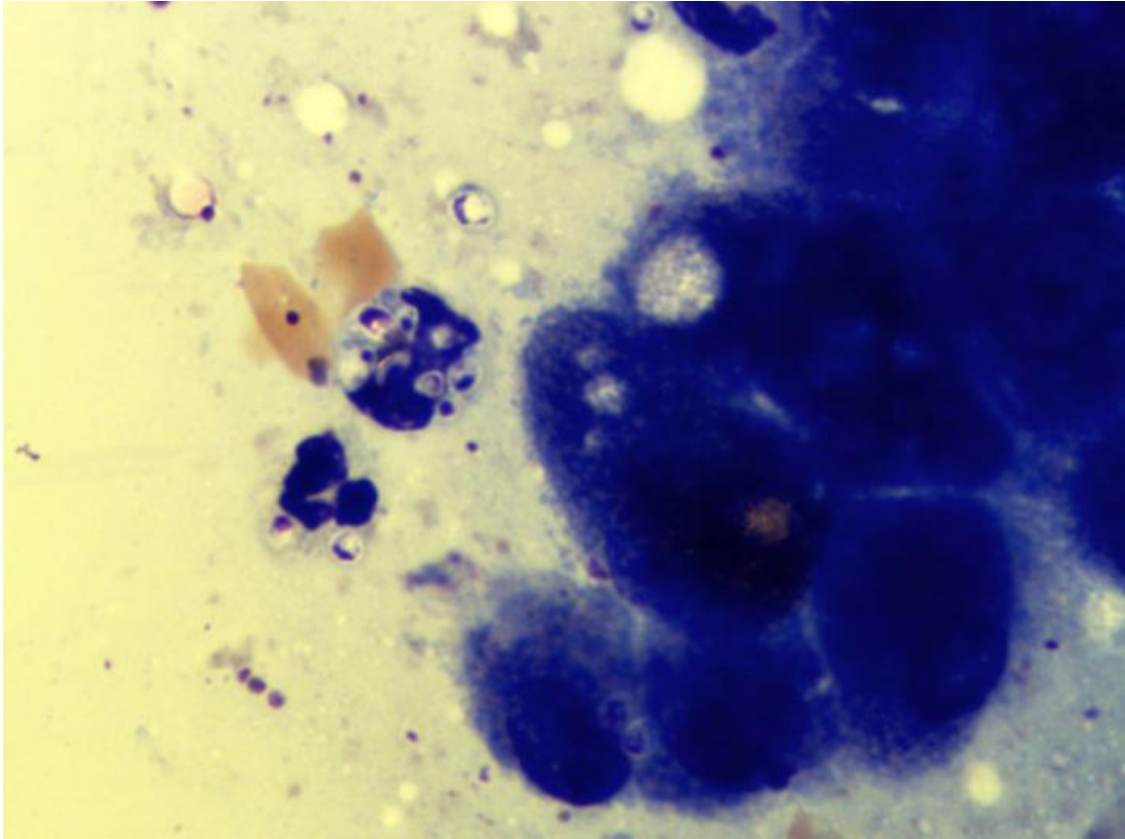


Figure 6: Hepatic aspirate, 100X objective, Wright's-Giemsa stain. A marked, mixed inflammatory infiltrate in the liver. *H. capsulatum* yeasts are seen within a neutrophil and an eosinophil as well as free throughout the background.

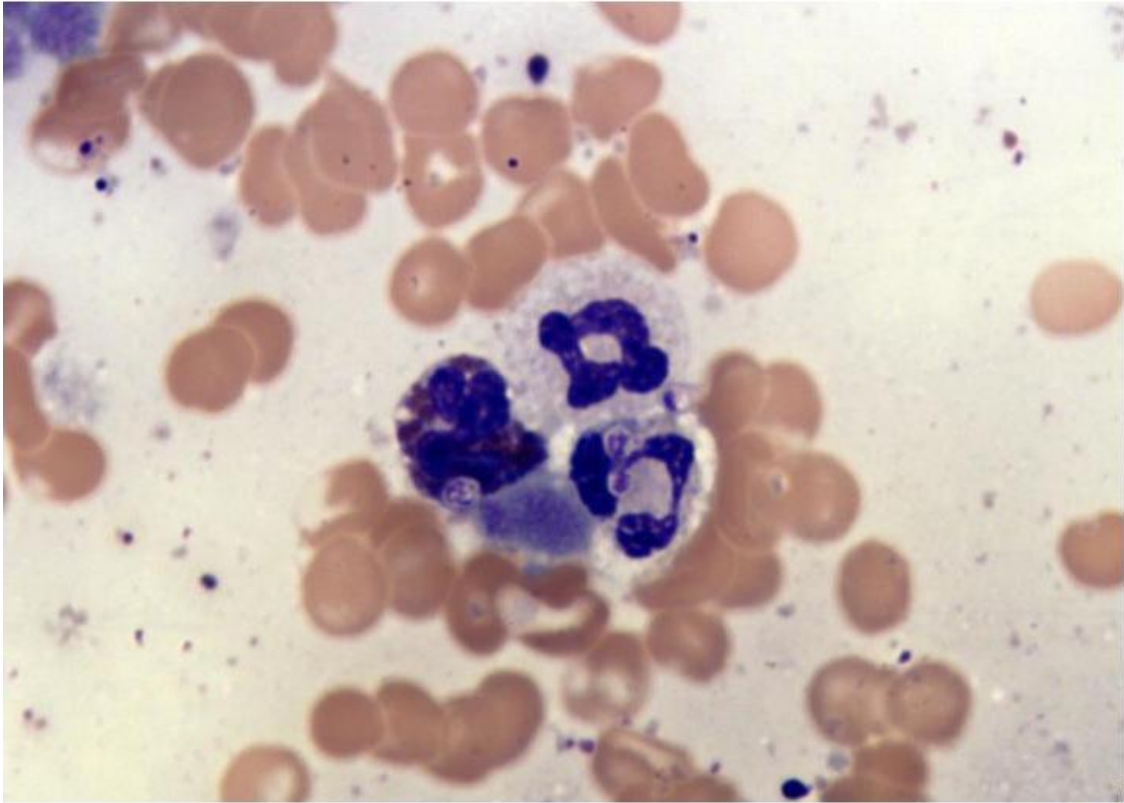
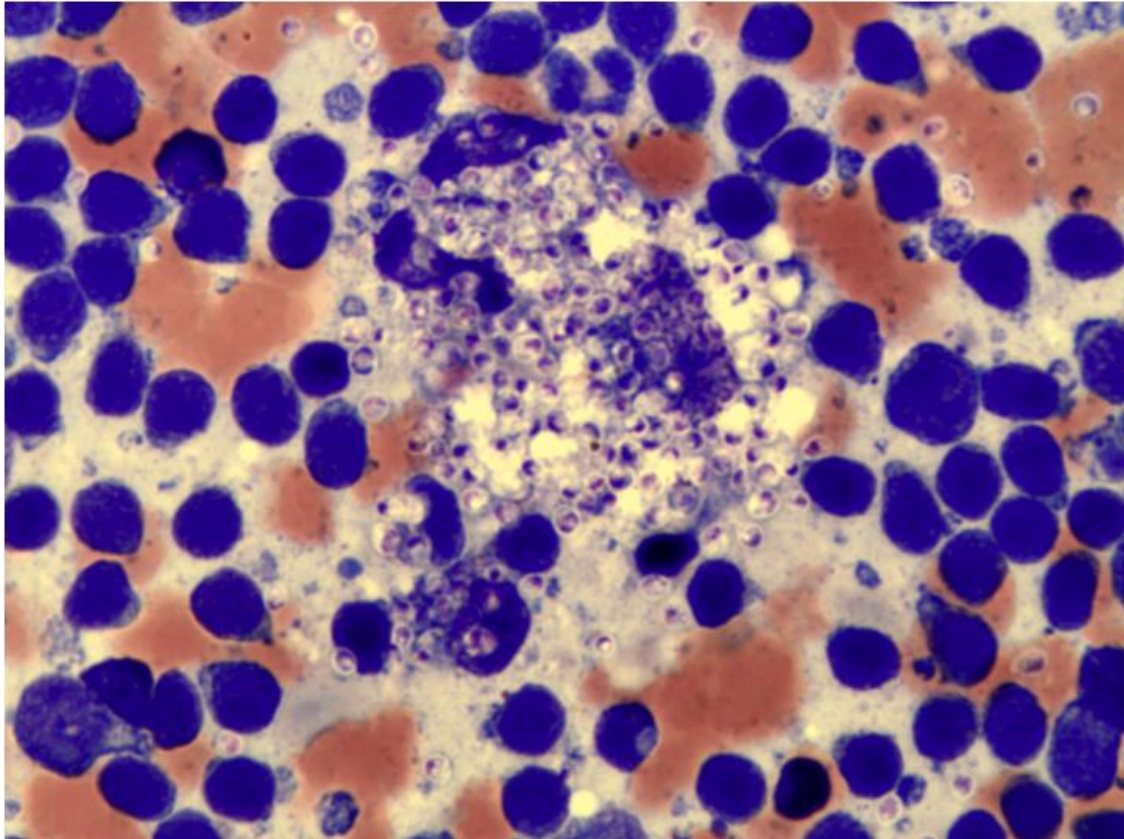


Figure 7: Splenic aspirate, 100X objective, Wright's-Giemsa stain. A macrophage laden with *H. capsulatum* organisms is noted, surrounded by a hyperplastic lymphoid population and additional free yeasts.



Splenic aspirate (Figures 7&8): The slides are of adequate staining and preservation of cellular detail with abundant hemodilution present against a pale basophilic background. A highly cellular splenic aspirate is present that contains numerous large, densely cellular splenic stromal elements that contain a small to moderate amount of blue-black granular material consistent with hemosiderin. The lymphoid population is heterogeneous in appearance, being predominantly comprised of small, well-differentiated lymphocytes with increased numbers of intermediate and large lymphocytes as well as plasma cells. Extramedullary hematopoiesis is also frequently observed. Similar to the hepatic aspirate, a highly cellular pyogranulomatous inflammatory cell infiltrate is present. Frequent *H. capsulatum* organisms are noted throughout the background, embedded within stromal elements, and phagocytized within leukocytes. No neoplastic cells are seen.

Figure 8: Splenic aspirate, 100X objective, Wright's-Giemsa stain. Two macrophages containing numerous *H. capsulatum* organisms are noted, admixed with a heterogeneous lymphoid population as well as numerous extracellular yeasts.

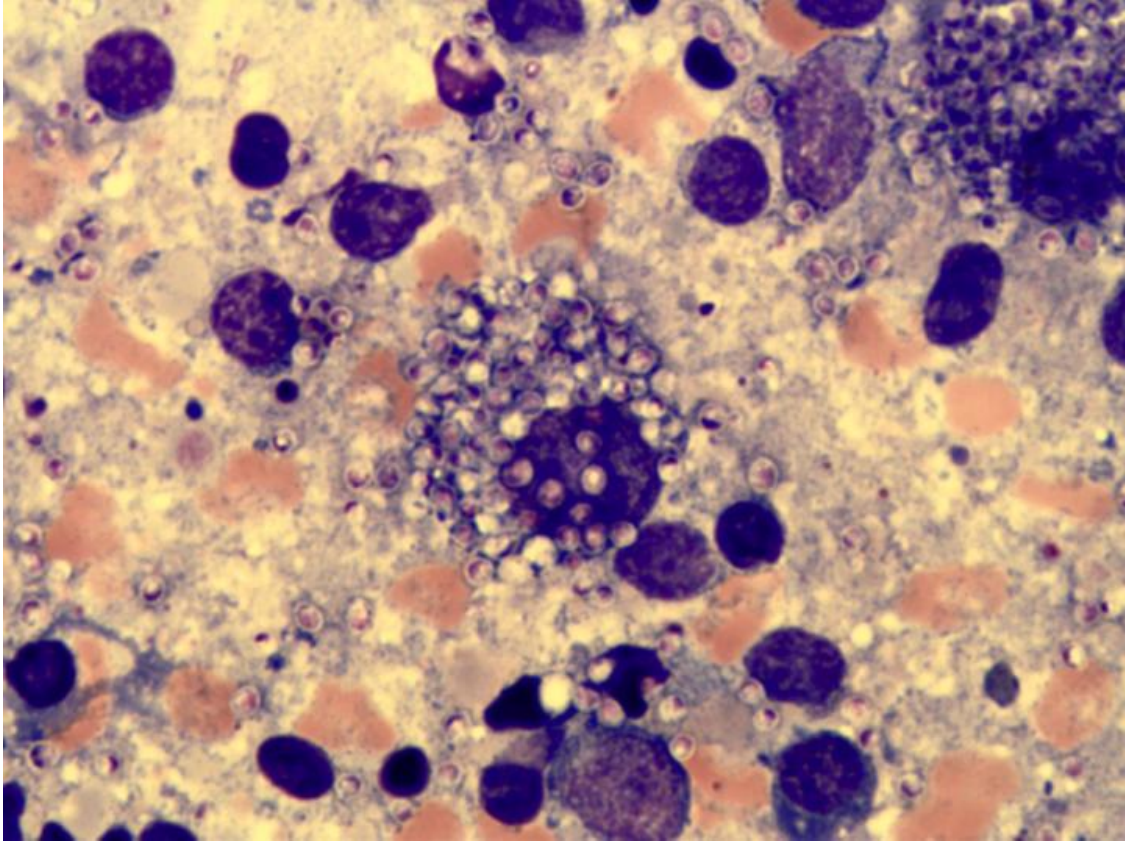
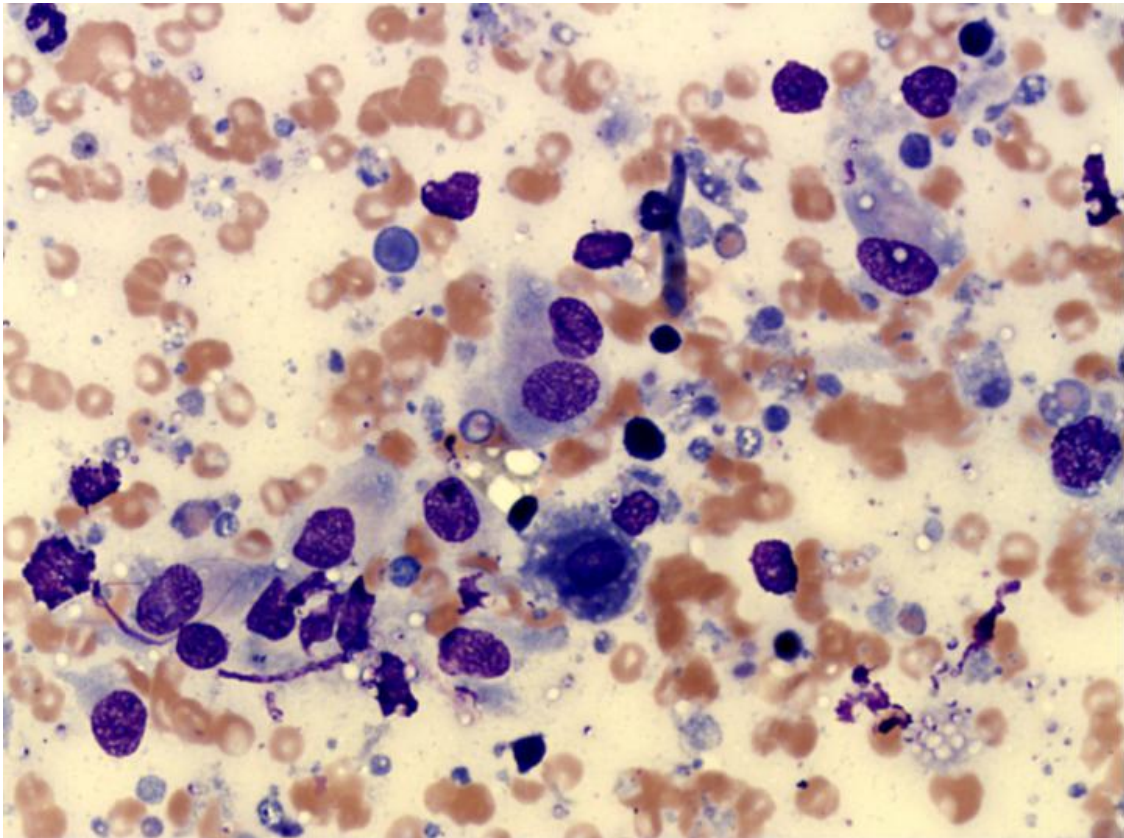


Figure 9: Lymph node aspirate, 50X objective, Wright's-Giemsa stain. A marked granulomatous inflammatory process is noted with a background of reactive lymphoid cells. Numerous *H. capsulatum* organisms are seen throughout the background as well as within macrophages and neutrophils. Lymphoglandular bodies and a small amount of degenerate cellular material are also observed.



Mesenteric lymph node aspirate (Figure 9): A moderately cellular lymph node aspirate is present that consists of a mixed lymphoid population. Small, well-differentiated lymphocytes predominate with frequent intermediate and large lymphocytes as well as plasma cells. In addition, numerous macrophages are observed, and often contain one to many phagocytized *H. capsulatum* organisms. Macrophages also frequently contain phagocytized erythrocytes, compatible with recent hemorrhage into the lymph node. Several mats of mostly lysed leukocytes are noted. No neoplastic cells are seen.

Microscopic findings: Disseminated histoplasmosis, liver, spleen, and lymph node.

Additional Laboratory Testing

Histoplasmosis Galactomannan Antigen EIA Quantitative Assay (MiraVista Diagnostics)

Patient >39ng/ml (positive)

Reference Range: 0.6-3.0 = positive (low)
4.0-19.9 = positive (moderate)
20.0->39.0 = positive (high)
Results >39.0 ng/mL are above the highest calibrator and cannot be quantified

Case Outcome

The patient appeared stable after aspirates of the liver, spleen, and lymph node were harvested and was discharged. However, the patient presented a few hours later with the complaint of marked lethargy. The patient's hematocrit had dropped precipitously. Despite aggressive supportive care, the patient expired that evening. A necropsy was not permitted.

Case Discussion

Histoplasma capsulatum is a soil-borne, dimorphic fungus that is capable of causing systemic disease in humans, dogs, cats, and other animals (1). In the parasitic phase, *H. capsulatum* has a yeast-like morphology, whereas the nonparasitic phase is characterized by abundant mycelium (2). The organism is endemic throughout extensive regions of temperate and subtropical areas of the world; however, infection is most commonly reported in North and South America, India, and southeastern Asia (1). In North America, the Mississippi, Ohio, and Missouri River valley areas are the most common regions in which histoplasmosis is diagnosed (2, 3,4). Cases of histoplasmosis originating in New York are documented but relatively uncommon. However, the dog in this case was obtained from a breeder located in Kansas. Kansas is a midwestern state in the central region of the United States of America; the far south-central and southeastern regions of this state have a humid subtropical climate and the northeastern boundary of the state is formed by the Missouri River.

Histoplasmosis is generally acquired via inhalation of microconidia (5). *H. capsulatum* has enhanced sporulation in soil containing nitrogen-rich organic matter such as the feces of bats and birds. Although there is often an association between exposure to such organic matter and subsequent development of infection, cases have also been documented in animals housed exclusively indoors (1). The

environment in which the dog was housed at the breeder is unknown. After exposure and an incubation period of 12-16 days, the microconidia convert to the yeast phase in the lungs and subsequently are phagocytized by leukocytes of the mononuclear phagocyte system and undergo further intracellular proliferation (1,6). Infection may then be limited to the respiratory tract or disseminated throughout the body. In most patients with a competent immune system, infection is either eliminated or enters a state of dormancy during which reactivation of infection can occur if the patient becomes immunosuppressed (1). Since the dog was apparently healthy when purchased from the pet store, it is possible that infection was latent at that time and recrudesced secondary to stress incurred during transport to the pet store. Alternatively, the dog may have had an underlying condition resulting in an immunocompromised state. As a final consideration, it is possible that the dog developed infection via exposure to another infected dog during transport and was in the subclinical, incubatory stage at the time of purchase; transmission from dog to dog has been documented but it is unknown whether dogs or other animals can transmit the disease to humans (2).

Clinical signs of histoplasmosis are determined by organ systems affected. It is unusual that this patient had no apparent respiratory signs, since this is the organ system most commonly affected. Intestinal involvement is commonly reported, and transmission by ingestion has been hypothesized as a route of direct infection (2). However, it is also possible that intestinal involvement may occur as a feature of disseminated disease. However, no intestinal signs such as diarrhea were reported in this case, either.

In the case reported here, the patient's clinical complaints were nonspecific. Initial diagnosis would have been challenging without advanced imaging (i.e., abdominal ultrasound), had it not been for the unusual observation of numerous *H. capsulatum* organisms in the peripheral blood smear. Abdominal ultrasound was performed and revealed hepatosplenomegaly and mesenteric lymphadenopathy as the only abnormalities. The GI tract was unremarkable. After observation of the yeast in peripheral blood and the above-mentioned ultrasound abnormalities, aspirates of liver, spleen, and mesenteric lymph nodes were obtained in an effort to determine the extent of infection; the aspirates revealed extensive involvement despite the fairly mild clinical presentation.

The most commonly reported abnormality on CBC's from patients with disseminated histoplasmosis is a normocytic, normochromic, nonregenerative anemia, such as was the case here. Anemia of inflammatory/chronic disease is a likely cause of the anemia, with potential contribution from infiltration of the bone marrow and intestinal loss if intestinal involvement is present. The leukogram from affected patients is variable, but an inflammatory leukogram is relatively common and was noted in this case. Only rarely are *H. capsulatum* organisms visualized on peripheral blood films; when noted, they are seen within macrophages and neutrophils. Thrombocytopenia resulting from disseminated intravascular coagulation (DIC) may occur in patients with disseminated histoplasmosis.

Although a thrombocytopenia was documented in the original CBC from this patient, the CBC collected immediately prior to collection of aspirates from the liver, spleen, and mesenteric lymph node indicated that platelets were within the reference interval. However, the precipitous drop in the hematocrit in the hours following ultrasound-guided aspiration was suspected to be attributable to post-procedural hemorrhage. Since platelet mass should have been adequate for hemostasis, either a thrombopathia or a consumptive factor deficient coagulopathy/early DIC was considered the likely cause of the apparent hemorrhage. However, coagulation profiles and d-dimer testing were declined by the owner and therefore not performed in this patient.

As with clinical signs, abnormalities noted on serum biochemistry are variable and parallel the organ system(s) involved. The abnormalities appreciated on the serum biochemistry of this patient were fairly mild and nonspecific. Hypoalbuminemia may have been attributable to decreased hepatic synthesis, prolonged anorexia, and/or albumin's role as a negative acute phase protein during inflammatory disease (note that globulins were elevated). GI loss can also lead to hypoalbuminemia, but there was no ultrasonographic evidence of GI involvement, and the GI signs were minimal (vomiting only). Hypoglycemia was documented, but may have represented in vitro glucose consumption by blood cells and/or *H. capsulatum* organisms during specimen transport to the reference lab. Urea nitrogen, bilirubin, and cholesterol were within the reference interval for this patient, indicating hepatic function was preserved, at least to some extent. Urinary or pre- and post-prandial bile acid testing and coagulation profiles might have been useful in further evaluating hepatic function, but was not performed. Hypocalcemia and hypomagnesemia were observed on the serum biochemistry but were likely related to the hypoalbuminemic state of the animal rather than true decreases; the corrected calcium was within the reference interval. AST and CPK were concurrently elevated; while AST may be associated with liver or muscle damage, CPK is relatively muscle specific. Since ALT, which is considered to be more liver-specific in dogs, was not elevated, muscle damage (possibly due to an injection) was suspected to be most likely. ALP may be elevated in young, growing dogs. However, this patient should have been nearly full-grown at 6 months, and phosphorus was not concurrently elevated. One explanation for the elevated ALP was chronic stress with associated glucocorticoid release. Unfortunately, cortisol levels were not measured for confirmation. GGTP levels were also elevated; since both ALP and GGTP may increase with cholestatic disease, it is possible that this patient experienced mild or focal cholestasis which did not result in a subsequent hyperbilirubinemia. Mild hypertriglyceridemia was noted on the serum biochemistry; while this finding is most commonly associated with a normal, physiologic phenomenon, a repeat fasting blood sample was not collected for verification. Total T4 was decreased in this patient, and was most likely due to euthyroid sick syndrome.

Diagnosis of histoplasmosis is generally accomplished by fine-needle aspirates or biopsies of affected organs. Transtracheal wash and bronchoalveolar lavage

specimens may be diagnostic, as well; however, patients with histoplasmosis often have respiratory involvement which may be exacerbated by anesthesia used during the procedure. Fungal culture is strongly discouraged due to the potential for sporulation on culture medium and subsequent infection of individuals working with the cultures. Intradermal testing is not valid in animals. Antibody testing via serology can be unreliable (1, 3), but sensitivity may be improved with antigen testing as was performed in this case (7).

The prognosis for disseminated *H. capsulatum* infection is poor; the infection is often fatal. If the infection is confined to the lungs, the prognosis is usually better than if the gastrointestinal tract is affected. Treatment, if instituted, consists of systemic antifungal agents.

In conclusion, we report an unusual case of histoplasmosis in a young Yorkshire Terrier dog in which the clinical signs were generally vague and gave little indication of infection and the diagnosis was facilitated by the observation of *H. capsulatum* organisms in the blood.

References

1. Greene CE. Fungal diseases: histoplasmosis. In Greene CE (ed): Infectious Diseases of the Dog and the Cat, ed. 3. St. Louis, Missouri, Saunders-Elsevier, 2006, pp577-583.
2. Valli VEO. Hematopoietic system: histoplasmosis. In Maxie MG (ed): Jubb, Kennedy, and Palmer's Pathology of Domestic Animals, ed 5. St. Louis Missouri, Elsevier, 2007, pp299-302.
3. Smith JD. Histoplasmosis. In Cote E (ed): Clinical Veterinary Advisor: Dogs and Cats. St. Louis, Missouri, Elsevier, 2007, pp 525-527.
4. Kerl ME. Update on canine and feline fungal diseases. Vet Clin North Am Small Anim Pract 2003;33(4):721-747.
5. Krohne SG. Canine systemic fungal infections. Vet Clin North Am Small Anim Pract 2000;30:1063-1090.
6. Taboada J and Grooters AM. Systemic mycoses: histoplasmosis. In Ettenger SJ and Feldman EC (eds): Textbook of Veterinary Internal Medicine, ed. 6. St. Louis, Missouri, Elsevier, 2005, pp680-682.
7. Spector D, Legendre AM, et al. Antigen and antibody testing for the diagnosis of blastomycosis in dogs. J Vet Intern Med 2008;22:839-843.