Cytological diagnosis of multiple cutaneous and subcutaneous nodules in a dog

Contributors

Ignacio Amarillo Gómez[1], Rocío Saiz Álvarez[2], Javier Hernández Antona[1], Belén Benages Saura[2], Beatriz Agulla Pérez[3], Javier Martínez Caro[3], Antonio Meléndez Lazo[1]

[1] T-cito
[2] Internal Medicine Department, Veterinary Teaching Hospital of Catholic University of Valencia
[3] Veterinary Clinical Pathology Laboratory, Faculty of Veterinary Medicine, Autonomous University of Barcelona

Ignacio Amarillo Gómez – ignacio.amarillogomez@gmail.com

Specimen

Fine needle aspirate biopsy of cutaneous and subcutaneous nodules and blood smear

Signalment

A 7-year-old female Cocker Spaniel Dog

History

A 7-year-old female Cocker Spaniel presented with a 1-year history of several episodes of cutaneous and subcutaneous nodules or thickening appearing in the area of the right alar cartilage, treated with antibiotics and corticosteroids which lead to their disappearance for variable periods, only to recur later. Additionally, during the last visit, the owners found a new scapular nodule, and described episodes of intermittent soft stools.

Clinical findings

The abnormalities found during the physical examination were a suboptimal body condition score (3/9), generalized lymphadenopathy, more pronounced in the submandibular and right popliteal regions, bilateral external otitis, thickening of the right third eyelid and various subcutaneous and cutaneous nodules.

Hematology showed a moderate leukocytosis 36.03 (reference interval -RI-: 5.05-16.76 K/µL) with lymphocytosis 26.23K/µL (RI: 1.3-4.1 K/µL). Mild hypophosphatemia was found in the biochemistry.

Parameter	Value	Reference Range
Red Blood Cells (RBC)	6.42	5.65 - 8.87 M/µL
Hematocrit	43.3	37.3 - 61.7 %
Hemoglobin	14.3	13.1 - 20.5 g/dL
Mean Corpuscular Volume (MCV)	67.4	61.6 - 73.5 fL
Mean Corpuscular Hemoglobin (MCH)	22.3	21.2 - 25.9 pg
Mean Corpuscular Hemoglobin Concentration (MCHC)	33.0	32.0 - 37.9 g/dL
Red Cell Distribution Width (RDW)	17.4	13.6 - 21.7 %
Reticulocytes	111.7	10.0 - 110.0 K/µL
Reticulocyte Hemoglobin	21.9	22.3 - 29.6 pg
White Blood Cells (WBC)	**36.03**	5.05 - 16.76 K/µL
Segmented Neutrophils	8.95	2.95 - 11.64 K/µL
Lymphocytes	**26.23**	1.05 - 5.10 K/µL
Monocytes	0.55	0.16 - 1.12 K/µL
Eosinophils	0.27	0.06 - 1.23 K/µL
Basophils	0.03	0.00 - 0.10 K/µL
Platelets	254	148 - 484 K/µL
Mean Platelet Volume (MPV)	8.95	8,7 - 13,2 fL

Figure 1. Complete blood count. (*Procyte Dx*, IDEXX Laboratories, Inc., One IDEXX Drive Westbrook, Maine, USA)

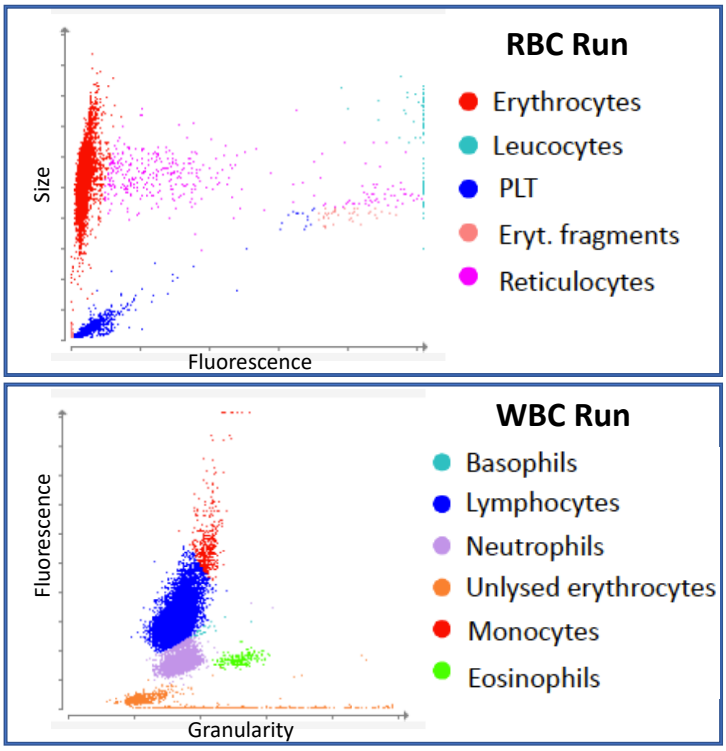

Figure 1b. Complete blood count – Dot plots. (*Procyte Dx*, IDEXX Laboratories, Inc., One IDEXX Drive Westbrook, Maine, USA)

Fine needle aspiration biopsy of various cutaneous and subcutaneous nodules, as well as a blood smear from peripheral blood were performed, and samples were submitted to the laboratory for cytologic examination (Figures 2-5).

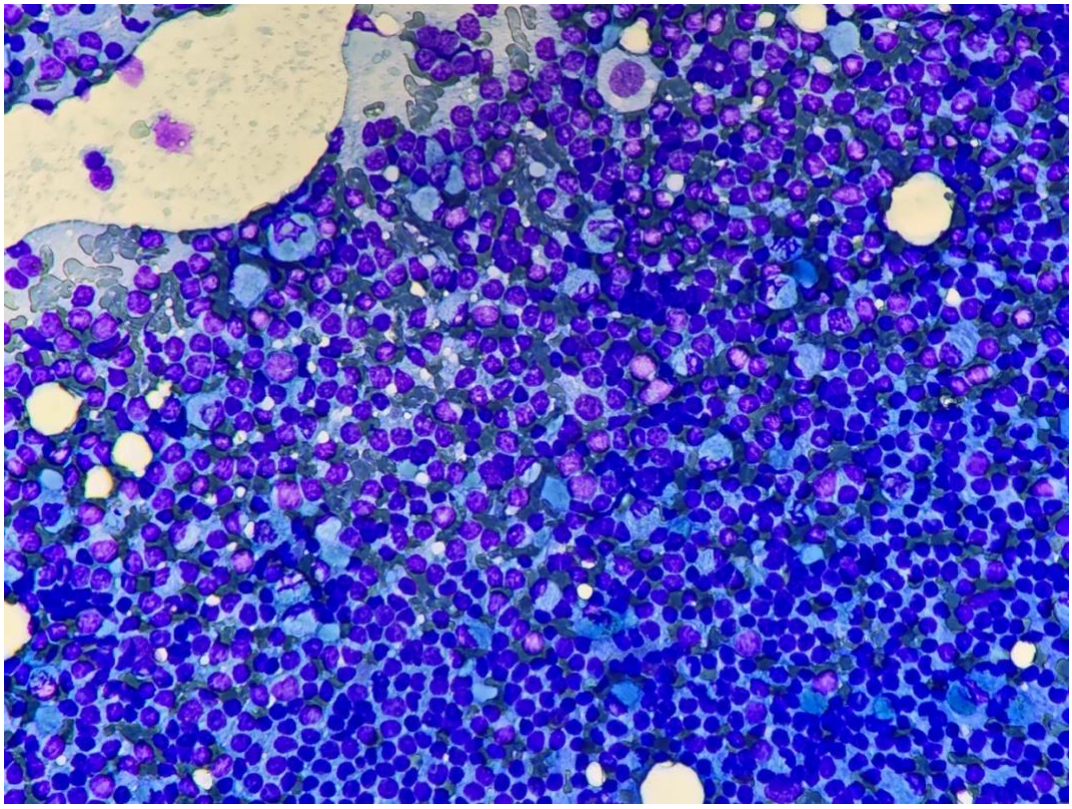

Figure 2. Fine needle aspirate of one of the cutaneous nodules, Wright Giemsa stain, 40x objective.

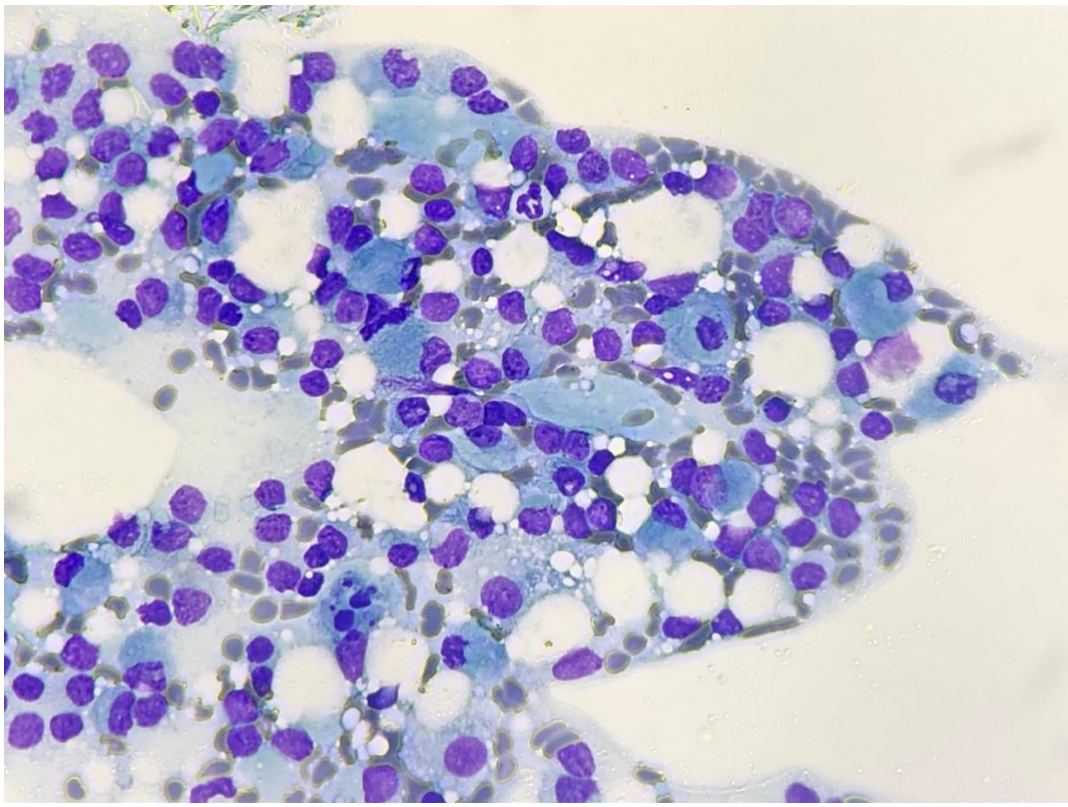

Figure 3. Fine needle aspirate of one of the subcutaneous nodules, Wright Giemsa stain, 100x objective.

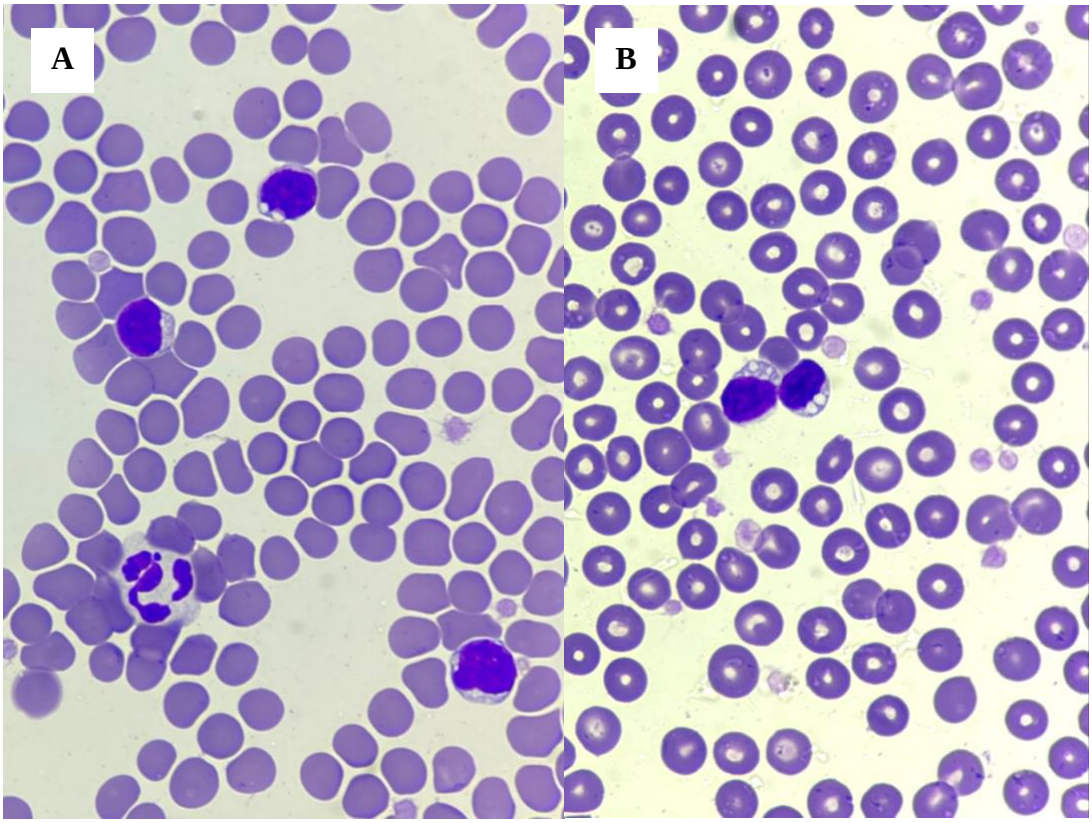

Figure 4 A-B. Peripheral blood smear, Wright Giemsa stain, 100x objective.

Questions

1. What is your description of the cytological and haematological samples?

2. Based on the clinical and pathological findings, what are your main differential diagnosis?

3. What additional tests would you use for confirming a diagnosis and further characterize it?

1. **What is your description of the cytological and haematological samples?**

Description
Cytologic examination revealed a heterogeneous lymphoid population, predominantly consisting of small cells, with lesser proportions of medium and large lymphocytes. The small to intermediate lymphocytes had scant to moderate amounts of pale blue cytoplasm, occasionally with small light blue inclusions. The nuclei were eccentrically placed, with rounded, sometimes irregular or indented morphology, and dense, occasionally clumped chromatin, and inconspicuous nucleoli. Low numbers of scattered mitotic figures were observed.
There was a moderate number of cells showing Mott cell differentiation with numerous inclusions of variable size and shape consistent with Russell bodies, that frequently displaced and compressed the nuclei. Occasional macrophages were also found.

In the blood smear, lymphocytes appeared homogeneous and were small to intermediate in size. They had scant light blue cytoplasm and often contained clear vacuoles of variable size.

2. **Based on the clinical and pathological findings, what are your main differential diagnosis?**

Differential diagnosis
The main suspicion was a small to intermediate cell lymphoma with Mott cell differentiation with circulating neoplastic cells (leukemic), as a cutaneous neoplasia or part of a multicentric lymphoma.

3. **What additional tests would you use for confirming a diagnosis and further characterize it?**

Additional testing
Further tests to better characterise the process would include staging through sampling for cytologic examination of different organs, biopsy and histopathological examination of the cutaneous and subcutaneous lesions and immunophenotyping through flow cytometry of the lesions/peripheral blood.

Follow up and test results

Samples were taken for histopathological examination from the lesion on the nose and from cutaneous and subcutaneous nodules, yielding fragments of lesions that presented similar characteristics. In the skin fragments (nose, figure 5), expanding the dermis and obliterating the cutaneous adnexa, a poorly demarcated and non-encapsulated neoplasia composed of nests and monolayer sheets of round cells supported by a moderate pre-existing fibrovascular stroma was observed. The neoplastic cells exhibited indistinct borders, scant to moderate amounts of eosinophilic cytoplasm, and a central rounded nucleus of small to intermediate size (1.5-2 times the size of a red blood cell) with marginated chromatin and one basophilic nucleolus. Three mitoses were detected in an area of 2.37 mm^2 (10 fields at 400x magnification). The histopathological diagnosis was non-epitheliotropic cutaneous lymphoma.

Fine needle aspiration was also performed on spleen (Figure 6), submandibular, pre-scapular, and popliteal (Figure 7) lymph nodes, revealing a lymphoid population and Mott cells similar to those described in the cutaneous and subcutaneous masses.

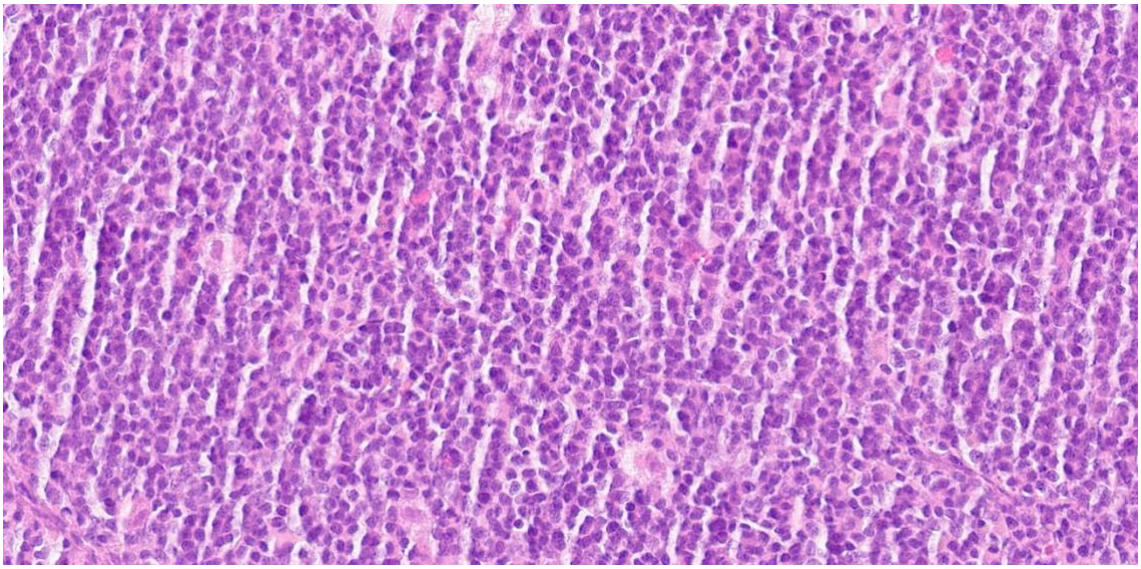

Figure 5. Histopathology, skin fragment nose. (H&E)

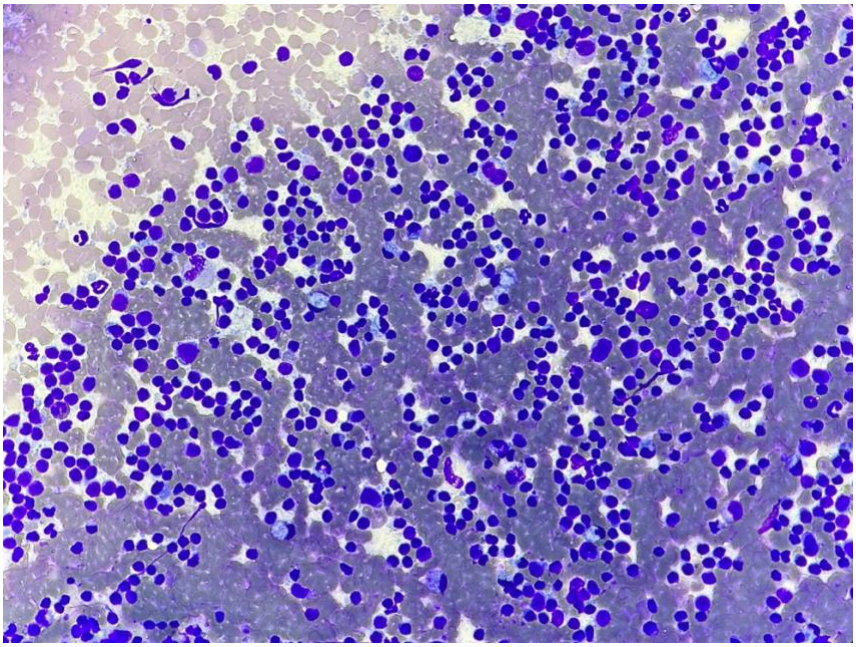

Figure 6. FNA spleen. Wright Giemsa stain, 40x objective.

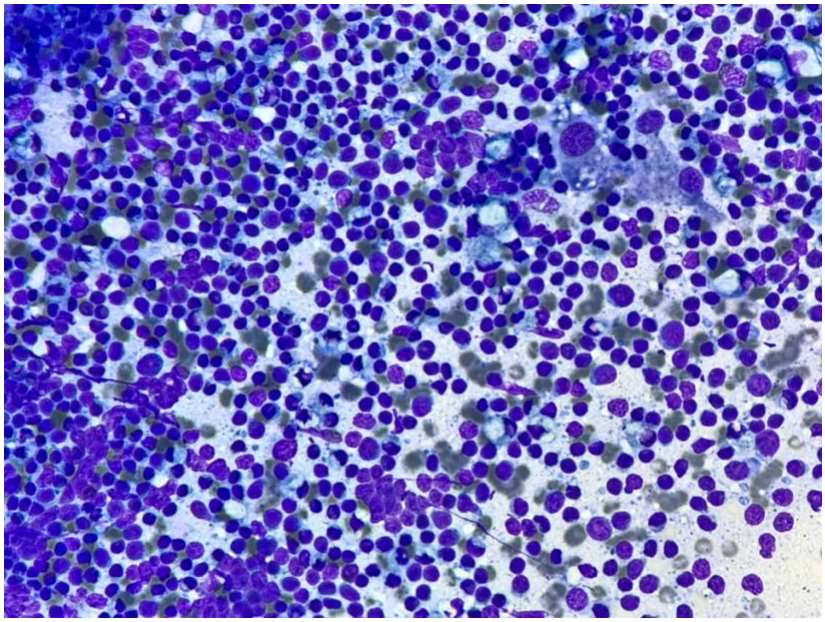

Figure 7. FNA of popliteal lymph node. Wright Giemsa stain, 40x objective.

However, considering the indolent clinical course of the disease, along with the results of the biopsy and cytology, it was necessary to characterize the type of lymphoma.

The animal's guardians consented to perform flow cytometry using samples from one of the cutaneous lesions and peripheral blood. The antibodies used included CD45, CD4, CD8, CD5, CD21, CD3, CMHII, CD25, CD18, CD34, CD14, CD79α, and Ki67.

The results of the cutaneous lesion revealed a predominant population of small to intermediate cells (98%), with positive staining for CD45 (94%), CD18 (98%), CD21 (94%), CMHII (98%), low expression of Ki67 (2%), and negative for the rest of the markers used. In peripheral blood, 75% of cells with the same phenotype were identified.

In summary, following the interpretation of all clinicopathological findings, the diagnosis indicated a B-cell lymphoproliferative process characterized by small to intermediate cells with Mott cell differentiation. This process involved cutaneous, subcutaneous, and various organs, with the presence of circulating neoplastic cells (leukemic or stage V).

Because the animal showed no clinical symptoms, the owners declined treatment despite the oncologist's recommendations, leading to an inability to follow up. Eleven months post-diagnosis, the dog was euthanized due to a deterioration in its clinical condition, marked by severe cachexia and the enlargement of cutaneous and subcutaneous lesions.

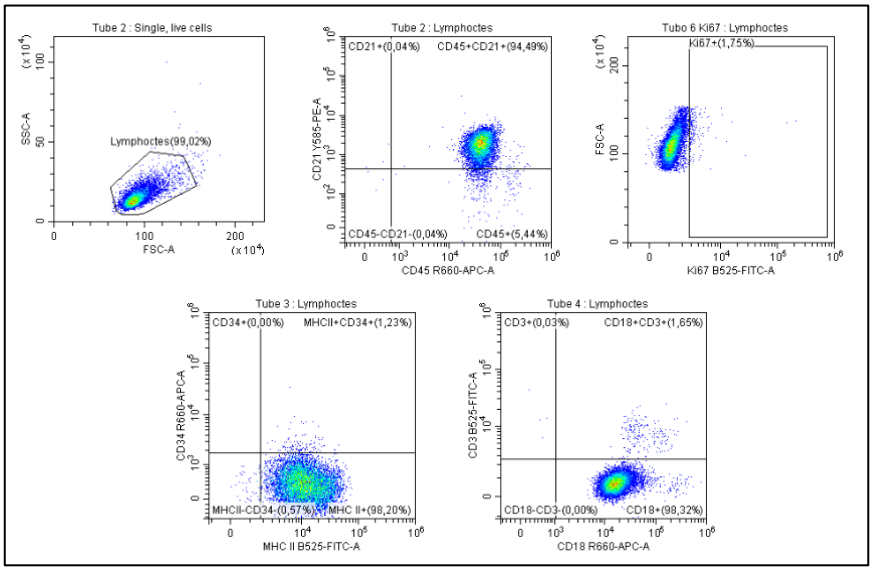

Figure 7. Flow cytometry of cutaneous nodule performed on the CytoFLEX LX.

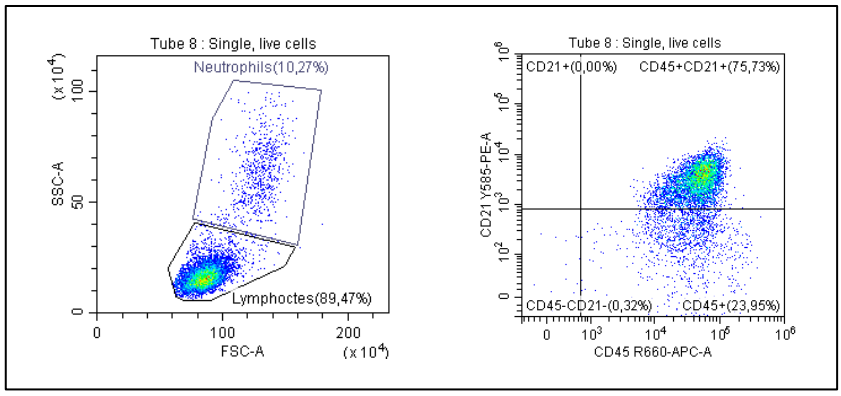

Figure 8. Flow cytometry of peripheral blood performed on the CytoFLEX LX.

Discussion

Lymphoma is a relatively common canine tumour, with multicentric and intestinal distribution as the two most common presentations. The majority of canine lymphomas exhibit the presence of B-cell markers, documented at rates ranging from 58.9% to 73.9%. Conversely, occurrences of B-cell lymphoma featuring Mott cell differentiation or Mott cell lymphoma (MCL) are infrequently reported, although there are a few documented cases in dogs (Kodama et al., 2008; De Zan et al., 2009; Stacy et al., 2009; Seelig et al., 2011; Snyman et al., 2013; Kol et al., 2013; Woo-Sub et al., 2022; Ohmi et al., 2023).

Cases of MCL generally affect abdominal organs (e.g., stomach, intestines, spleen, liver, lymph nodes, etc.) and depending on the case, size of lymphocytes can vary from small to intermediate or large. Cutaneous or subcutaneous lesions in MCL have not been previously reported to the author's knowledge.

Lymphocytosis is a relatively common finding in the cases described, sometimes associated with hematological abnormalities (e.g., mild anemia or thrombocytopenia), although it is an inconsistent finding. Typically, this lymphocytosis consisted of neoplastic lymphocytes (regardless of size, usually large), although there are cases without lymphocytosis where a leukemic phase of the disease was still confirmed (Stacy et al., 2009). The circulation of neoplastic cells in lymphomas does not always correlate with an aggressive clinical course, as seen in T-Zone lymphoma (de Sena et al., 2023) and likely in this case as well. As with the other cases described, we did not perform a bone marrow study due to the absence of cytopenias, assuming that it would not provide us any benefits to perform it.

Survival times after diagnosis of Mott cell lymphoma can vary from 0 days since it is diagnosed due to the severity of the clinical presentation (Snyman et al., 2013), to even 2667 days, when treated with various chemotherapeutic protocols (Ohmi et al., 2023). The limited number of reported cases complicates prognostic predictions; nevertheless, widespread nodal and extranodal involvement was frequently observed in almost every case, and the response to chemotherapy was restricted.
The prolonged survival time (11 months approximately) despite the lack of chemotherapeutic treatment suggest a slow progression of the disease in this case, supported by the small size of the cells, the low expression of Ki67 and the low mitotic index.

A diagnosis of lymphoma with Mott cell differentiation was initially favored on the basis of the cytologic features of fine-needle aspirates, which revealed a biphasic population of lymphoid cells: atypical, small to medium-sized lymphocytes and Mott cells.

Other considered differential diagnoses included plasma cell neoplasia (ie, malignant plasmacytoma and multiple myeloma). However, the cytomorphologic features of the neoplastic population, which did not contain an obvious plasma cell population yet did contain a substantial population of Mott cells, served to rule out these differential diagnoses.
Additionally, the atypical lymphocyte population was found to express CD21, which is not known to be expressed on canine plasma cells (Seelig et al., 2011).

Further tests such as periodic acid-Schiff stain, immunohistochemistry, immunocytochemistry, PCR for antigen receptor rearrangement (PARR), electron microscopy, etc. could have been applied for more reliable identification of the neoplastic cells and their cytoplasmic vesicles. In some cases, cytologic, histologic, and ultrastructural examinations showed little evidence of plasma cell differentiation. It appears that some lymphoblasts may evolve directly into Mott cells without first transforming into plasma cells, implying that lymphoblasts may serve as an initial phase in the development of neoplastic Mott cells (Stacy et al., 2009).

The limitations of this case include the lack of access to a greater number of diagnostic tests due to economic constraints, as well as the challenging patient follow-up. Furthermore, very little is known about the clinical course of this specific type of neoplasia, making it difficult to predict its behavior.

In conclusion, this case is a distinctive presentation of an uncommon lymphoma with an apparently non-aggressive clinical progression. Nonetheless, an initial cytological approach supported by histopathology and flow cytometry may suffice to obtain a presumptive diagnosis.

References

1. Kodama A, Sakai H, Kobayashi K, Mori T, Maruo K, Kudo T, Yanai T, Masegi T. (2008). B-cell intestinal lymphoma with Mott cell differentiation in a 1-year-old miniature Dachshund. *Veterinary Clinical Pathology*, 37(4), 409–415. doi: 10.1111/j.1939-165X.2008.00067.x.
2. Stacy NI, Nabity MB, Hackendahl N, Buote M, Ward J, Ginn PE, Vernau W, Clapp WL, Harvey JW. (2009). B-cell lymphoma with Mott cell differentiation in two young adult dogs. *Veterinary Clinical Pathology*, 38(1), 113–120. doi: 10.1111/j.1939-165X.2008.00101.x.
3. De Zan G, Zappulli V, Cavicchioli L, Di Martino L, Ros E, Conforto G, Castagnaro M. (2009). Gastric B-cell lymphoma with Mott cell differentiation in a dog. *Journal of Veterinary Diagnostic Investigation*, 21(5), 715–719. doi: 10.1177/104063870902100521.
4. Seelig DM, Perry JA, Zaks K, Avery AC, Avery PR. (2011). Monoclonal immunoglobulin protein production in two dogs with secretory B-cell lymphoma with Mott cell differentiation. *Journal of the American Veterinary Medical Association*, 239(11), 1477–1482. doi: 10.2460/javma.239.11.1477.
5. Snyman HN, Fromstein JM, Vince AR. (2013). A rare variant of multicentric large B-cell lymphoma with plasmacytoid and Mott cell differentiation in a dog. *Journal of Comparative Pathology*, 148(4), 329–334. doi: 10.1016/j.jcpa.2012.08.002.
6. Kol A, Christopher MM, Skorupski KA, Tokarz D, Vernau W. (2013). B-cell lymphoma with plasmacytoid differentiation, atypical cytoplasmic inclusions, and secondary leukemia in a dog. *Veterinary Clinical Pathology*, 42(1), 40–46. doi: 10.1111/vcp.12003.
7. Kim WS, Song KH, Bae H, Yu D, Song JH. (2022). Mott Cell Differentiation in Canine Multicentric B Cell Lymphoma with Cross-Lineage Rearrangement and Lineage Infidelity in a Dog. *Veterinary Sciences*, 9(10), 549. doi: 10.3390/vetsci9100549.

8. Ohmi A, Tanaka M, Rinno J, Tsuboi M, Chambers JK, Uchida K, Goto-Koshino Y, Tomiyasu H, Ohno K, Tsujimoto H. (2023). Clinical characteristics and outcomes of Mott cell lymphoma in nine miniature dachshunds. *Veterinary Medicine and Science*, 9(2), 609-617. doi: 10.1002/vms3.975.
9. de Sena BV, de Mello BC, Horta RDS, Costa MP, Melo MM, Mariano RMDS, Giunchetti RC, Giuliano A, de Oliveira Paes Leme F, de Paula Sabino A, de Oliveira Paes PR. (2023). Extreme lymphocytosis in a dog with T-zone lymphoma. *Open Veterinary Journal*, 13(12), 1760-1768. doi: 10.5455/OVJ.2023.v13.i12.25.