Investigating anemia: a cold case

Calzolari Claudia[1], Magna Luca[1], Lombardo Gabriella[2]

[1] San Marco Veterinary Clinic and Laboratory, Veggiano (PD), Italy
[2] Centro Veterinario Lombardo, Mascalucia (CT), Italy

Specimen: K3EDTA Whole Blood and peripheral blood smear submitted for CBC and lymph nodes FNA for cytological evaluation and immunophenotyping.

Signalment: 10 years old, intact male, Yorkshire Terrier dog

History: the dog presented with generalized lymphadenomegaly

Clinical Findings: a K3 EDTA whole blood sample was sent to our laboratory for staging purposes and for the impossibility to accurately determine the hematocrit which was surprisingly low (25%) on an automated analyzer; in particular, the Hct was underestimated compared to a PCV performed on the same sample (45%).
The results of a CBC performed on ADVIA 2120i in our laboratory are reported in Table 1.
Of note the presumptive macrocytic anemia with a double population on the RBC V/HC cytogram (Fig 1), consistent with RBC agglutinates, leukopenia and reticulocytosis, with abnormal gating on the Retic Scatter Absorption graph.
Given the substantial difference between MCHC and CHCM, the analyzer provided the CHCM-CE (CHMC Comparison Error) flag.

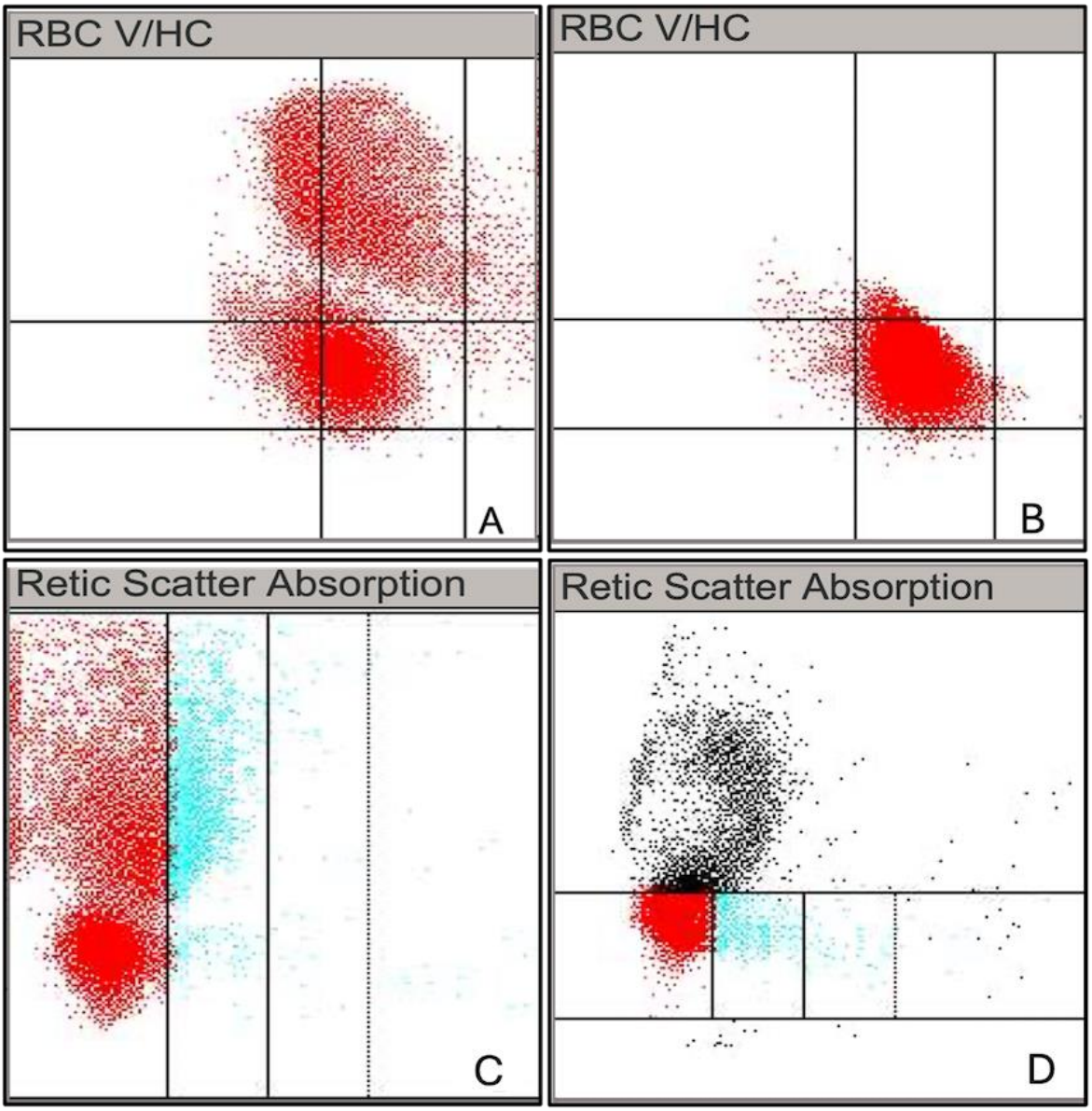

Figure 1 RBC V/HC scattergram (A) and Retic scattergram (C) on an ADVIA 2120i analyzer from the patient performed at Room Temperature. RBC V/HC scattergram (B) and Retic scattergram (D) from a normal dog for comparison.

Table 1 Results from the CBC performed upon arrival at room temperature (RT). Abnormal results are reported in bold.

	Result (RT)	Reference Interval
RBC (x10^6 cells/µL)	**2.78**	5.7-8.6
HGB (g/dL)	15.9	14.1-21.2
HCT (%)	**26.3**	39.0-59.2
MCV (fL)	**94.8**	63.1-72.6
MCH (pg)	**57.3**	21.8-25.4
MCHC (g/dL)	**60.5**	33.3-36.8
CHCM (g/dL)	**30.1**	34.3-37.8
CH (pg)	**28.5**	22.0-26.0
RDW %	**38.0**	11.6-14.7
HDW g/dL	**3.75**	1.63-2.22

PLT (x10^3 cells/µL)	285	174-479
MPV fL	**16.5**	8.9-15.0
WBC (x10^3 cells/µL)	**3.88**	5.0-12.9
NEUT (x10^3 cells/µL)	**1.81**	3.6-9.3
LYMPH (x10^3 cells/µL)	1.81	1.7-3.8
MONO (x10^3 cells/µL)	**0.14**	0.2-0.8
EOS (x10^3 cells/µL)	**0.07**	0.1-1.2
BASO (x10^3 cells/µL)	0.01	0-0.1
RETIC (x10^3 cells/µL)	203.2	8.4-129.3

The examination of a blood smear performed upon sample collection was unremarkable (Fig. 2), and neither polychromasia nor leukopenia were seen. Whereas, on a blood smear performed upon arrival at our laboratory, numerous and voluminous RBC agglutinates were seen (Fig. 3) and neither leukopenia nor polychromasia were observed.

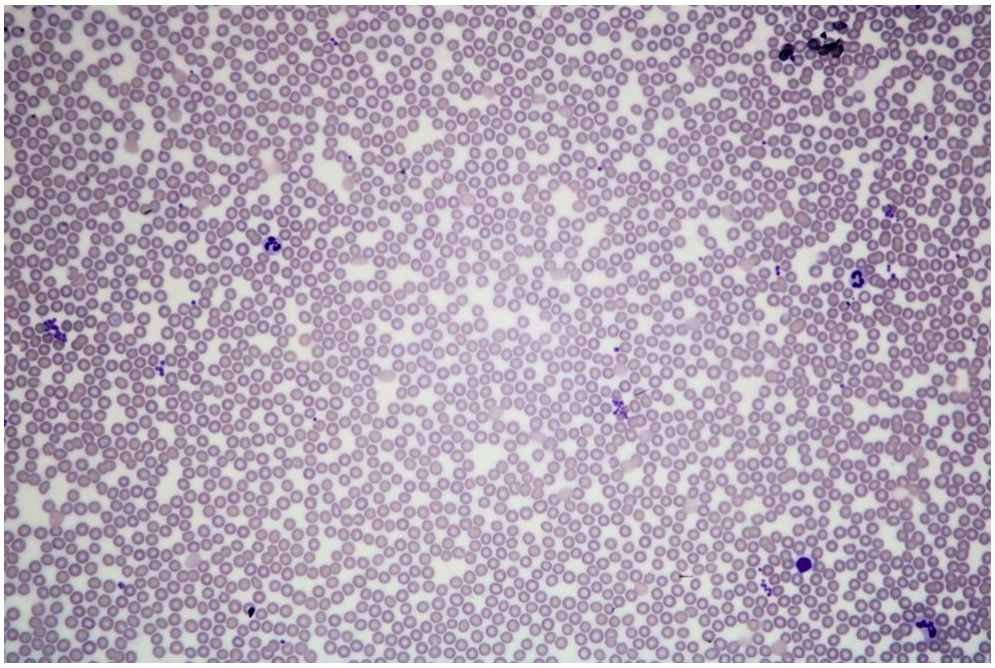

Figure 2 Blood smear upon sample collection (Diff-Quick, 40x).

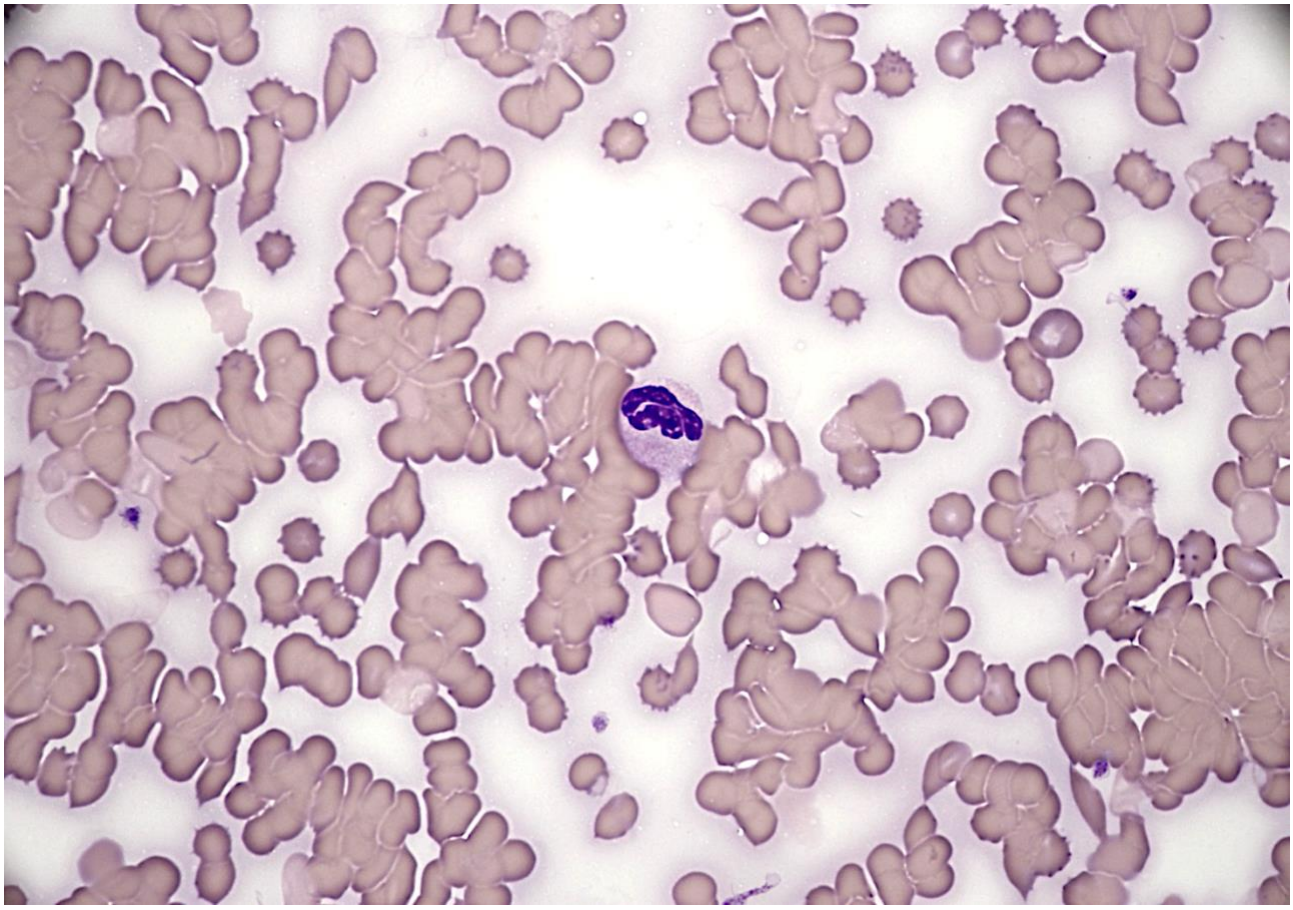

Figure 3 Blood smear performed upon arrival at the laboratory 24h after collection (Diff Quick, 100x)

On cytological evaluation of the lymph nodes, a monomorphic population of numerous intermediate to large lymphocytes with frequent cells with intracytoplasmic globules (Mott-cells), rare small lymphocytes, macrophages and neutrophils were seen. The sample was considered consistent with large cell lymphoma. On immunocytochemistry most of the large cells were positive for CD79a (B lymphocytes) (Figure 4) and only rare small cells were positive for CD3 (T lymphocytes).

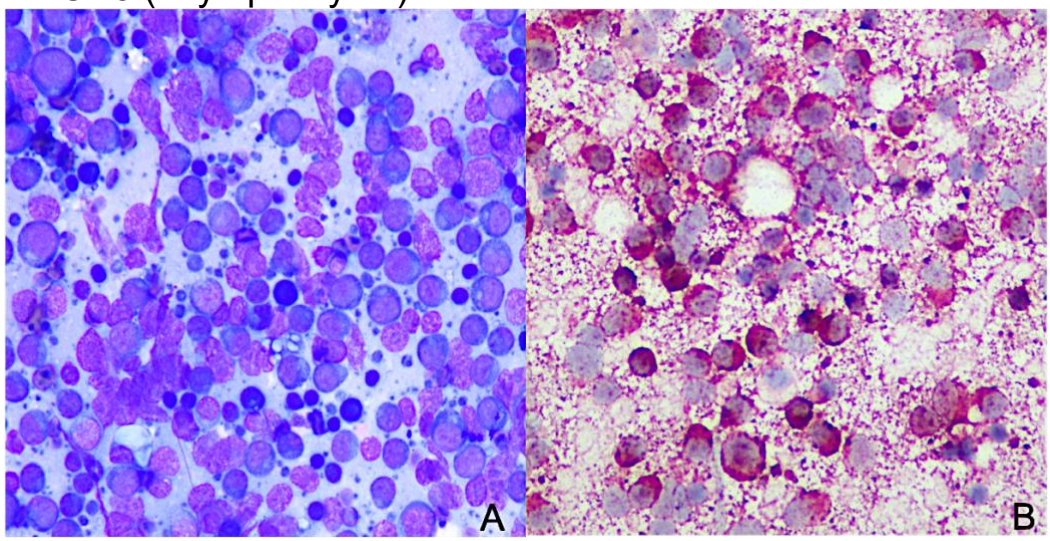

Figure 4 Cytology (MGG, 40x) and ICC (CD79a, 40x) of an enlarged lymph node.

Questions

1. Which conditions (pathological and artifactual) could possibly cause RBC agglutination?
2. What would you suggest to obtain a reliable automated analysis?

Which conditions (pathological and artifactual) could possibly cause RBC agglutination?

Differential diagnosis for agglutination included Immune Mediated Hemolytic Anemia (IMHA), hyperproteinemia (immunoglobulins or fibrinogen), anti-coagulant induced agglutination and cold agglutinins.

IMHA was deemed less probable because the dog was not anemic and because of the lack of signs of hemolysis on the blood smear (spherocytosis) and lack of a regenerative response (polychromasia).

What would you suggest to obtain a reliable automated analysis?

To rule out in vitro agglutination induced by cold agglutinins or EDTA, the CBC should be rerun with the sample prewarmed at 37°C and from whole blood collected in a different anticoagulant (e.g. Na citrate).

Since EDTA-anticoagulated blood was the only available sample, to prove the presence of cold agglutinins we warmed the samples at 37°C for 1 hour before rerunning the analysis. As shown in figure 5, on the RBC V/HC scatter, the events consistent with aggregates were no longer present and the Hct matched the PCV result. Also, although the difference between MCHC and CHCM were still present, it notably decreased.

On the Retic Scatter Absorption graph (Figure 5) the populations were separated with the common appearance of gates, consequently, the spurious reticulocytosis was no longer detected, as well as the artifactual leukopenia (Table 2).

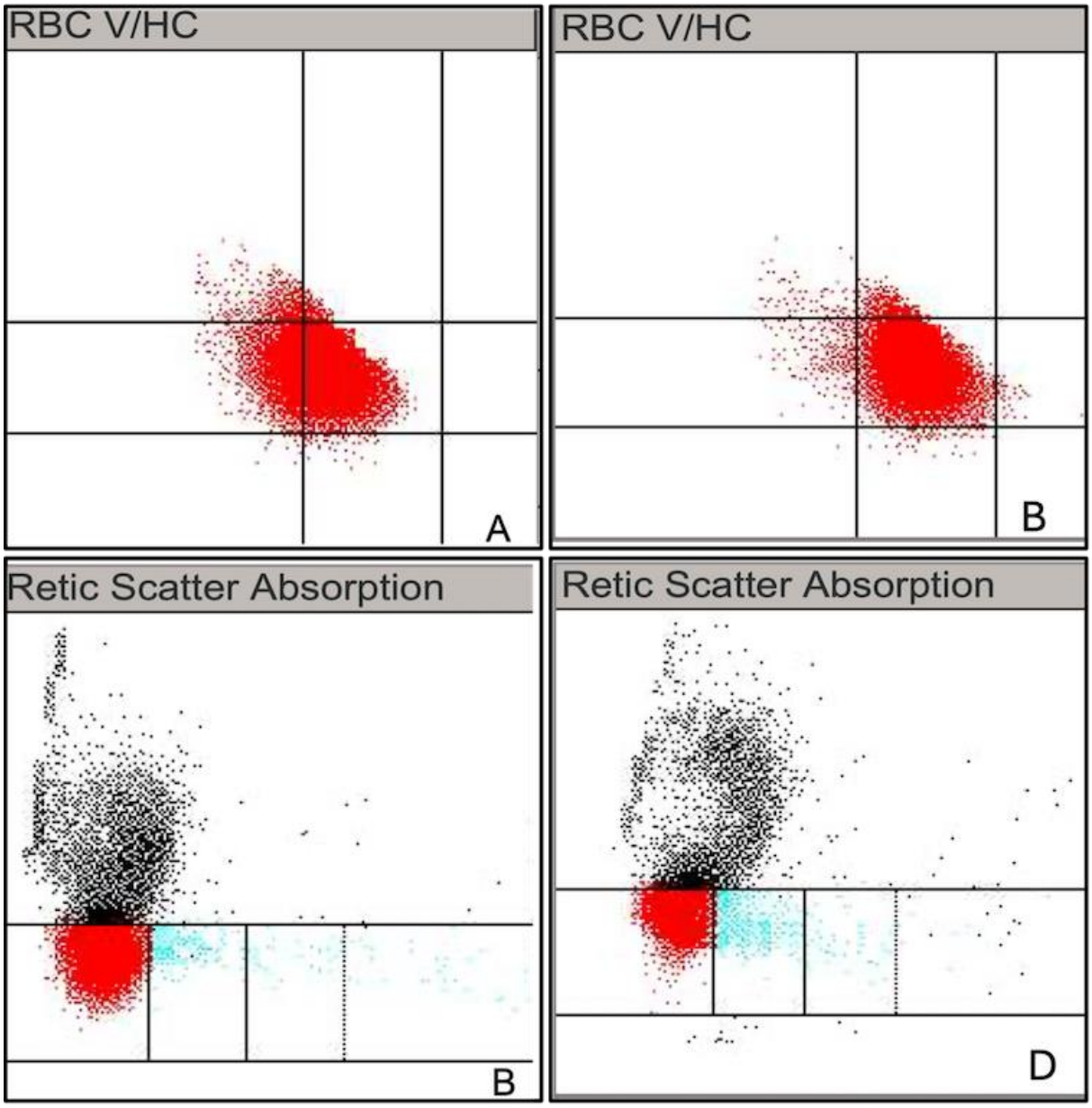

Figure 5 Figure 1 RBC V/HC scattergram (A) and Retic scattergram (C) on an ADVIA 2120i analyzer from the patient. The CBC was performed after warming the sample at 37°C. RBC V/HC scattergram (B) and Retic scattergram (D) from a normal dog for comparison.

A Saline Agglutination Test (1:4 dilution) at different temperatures was performed and it tested positive at 4°C, and Room Temperature (RT) but not at 37°C. Also, the Saline Agglutination Test was performed on washed RBCs and although less prominent, positivity at 4°C and RT was still detectable (Fig. 6).

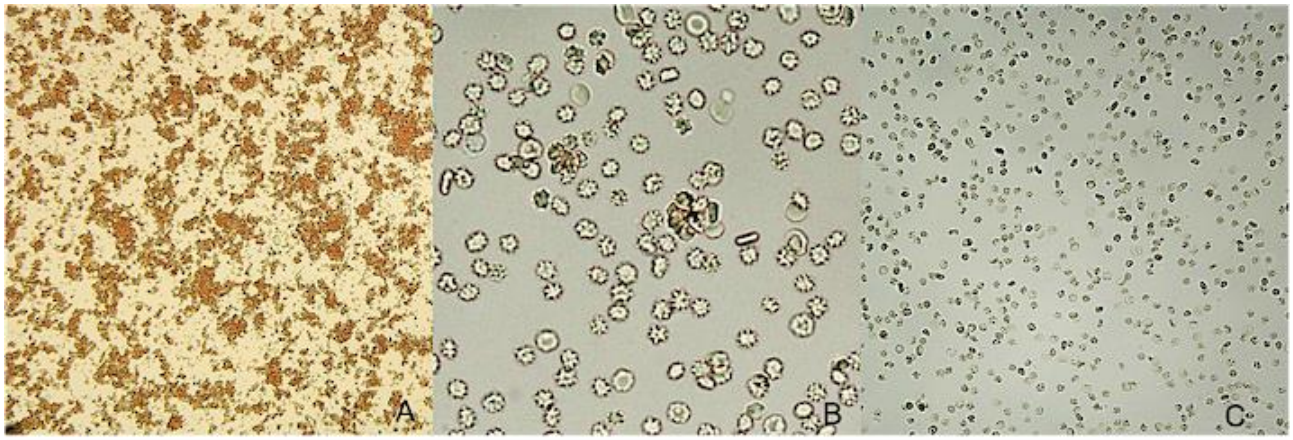

Figure 6 Saline Agglutination test (A) at 4°C before RBC washing and at 4°C (B) and 37°C (C) after RBCs washing.

Table 2 Results of the CBC performed upon arrival at room temperature RT and after warming the sample at 37°C. Abnormal results are reported in bold.

	Result (37°C)	Result (RT)	Reference Interval
RBC (x10^6 cells/µL)	6.69	**2.78**	5.7-8.6
HGB (g/dL)	15.5	15.9	14.1-21.2
HCT (%)	47.5	**26.3**	39.0-59.2
MCV (fL)	71.1	**94.8**	63.1-72.6
MCH (pg)	23.2	**57.3**	21.8-25.4
MCHC (g/dL)	**32.7**	**60.5**	33.3-36.8
CHCM (g/dL)	**29.8**	**30.1**	34.3-37.8
CH (pg)	**21.1**	**28.5**	22.0-26.0
RDW %	12.4	**38.0**	11.6-14.7
HDW g/dL	2.22	**3.75**	1.63-2.22
PLT (x10^3 cells/µL)	**154**	285	174-479
MPV fL	**20.6**	**16.5**	8.9-15.0
WBC (x10^3 cells/µL)	5.1	**3.88**	5.0-12.9
NEUT (x10^3 cells/µL)	**2.31**	**1.81**	3.6-9.3
LYMPH (x10^3 cells/µL)	2.42	1.81	1.7-3.8
MONO (x10^3 cells/µL)	0.21	**0.14**	0.2-0.8
EOS (x10^3 cells/µL)	0.12	**0.07**	0.1-1.2
BASO (x10^3 cells/µL)	0.04	0.01	0-0.1
RETIC (x10^3 cells/µL)	27.3	203.2	8.4-129.3

On day 7, additional samples were requested for further investigations based on the aforementioned differential diagnosis. Despite macroscopic agglutination in the tube, a complete blood count was also performed on Na-citrated anticoagulated blood to rule out EDTA-dependent agglutination of RBC. Also, from Na-citrated anticoagulated blood the agglutination and the artifactual changes in RBC indices were present at RT but not at 37°C. Results of the biochemistry profile showed a slight increase in AST and ALT.

To rule out hyperfibrinogenemia a coagulation profile with fibrinogen measurement was evaluated and PT, aPTT and fibrinogen were in the reference intervals.
Capillary Zone electrophoresis of serum protein performend on a Sebia Capillarys 2 (Sebia, Lisses Evry Cedex, France) revealed a monoclonal peak in the gamma region (Fig 7).

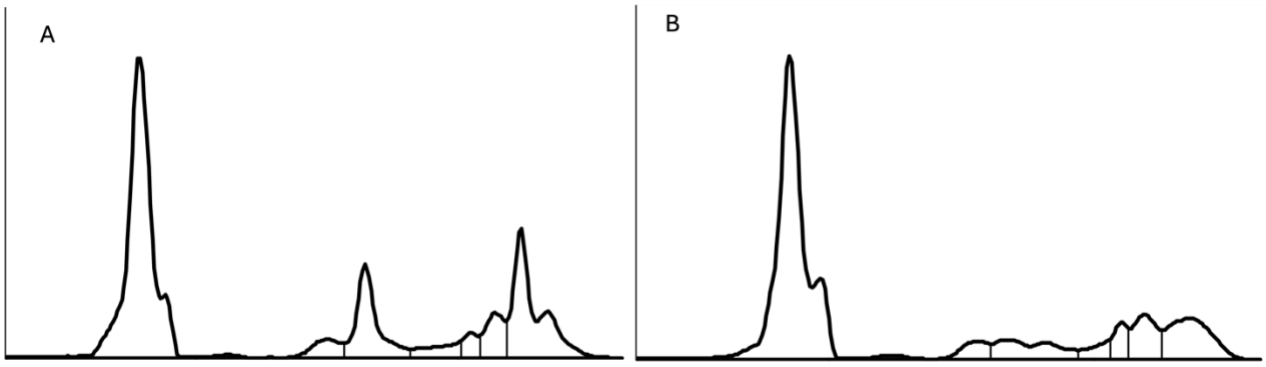

Figure 7 Capillary Zone Electrophoresis from the serum of the patient (A) and the serum of a normal dog (B) for comparison.

	Result	Reference Interval	Result	Reference Interval
Total Proteins			7.6 g/dL	6.2-7.3 g/dL
Albumin	**50.3 %**	55.3-60.7 %	3.8 g/dL	3.7-4.1 g/dL
Alpha	16.9 %	14.3-17.7 %	1.3 g/dL	0.9-1.3 g/dL
Alpha 1	3.8 %	3.1-5.3 %	0.3 g/dL	0.2-0.3 g/dL
Alpha 2	13.1 %	10.1-13.6 %	**1.0 g/dL**	0.7-0.9 g/dL
Beta	**12.1 %**	12.3-15.6 %	0.9 g/dL	0.8-1.1 g/dL
Beta 1	**3.6 %**	2-3.3 %	0.3 g/dL	0.1-0.3 g/dL
Beta 2	**2.5 %**	2.9-4.4 %	0.2 g/dL	0.2-0.3 g/dL
Beta 3	**6.0 %**	6.6-7.6 %	0.5 g/dL	0.4-0.5 g/dL
Gamma	**20.7 %**	9.7-13.7 %	1.6 g/dL	0.7-0.9 g/dL
A/G	**1.01**	1.24-1.54		

Based on the evidence of agglutination at RT and 4°C, the resolution of the agglutination after warming the sample at 37°C and the exclusion of other possible conditions determining agglutination, the presence of cold agglutinins was strongly suspected.
In order to confirm the presence of cold agglutinins (CA) serial dilutions of plasma were performed up to 1:128. After mixing the diluted plasma with the blood of the patient at 4°C, the agglutination persisted until the maximum dilution (Fig. 8).
A DAT test was also performed using gel technology (Canine Gel Test DAT, Alvedia, Limonest, France) both at 37°C and 4°C. At 37° the patient tested positive (1+). At 4°C, despite testing strongly positive, the result could have not been considered due to the impossibility to obtain a negative control.

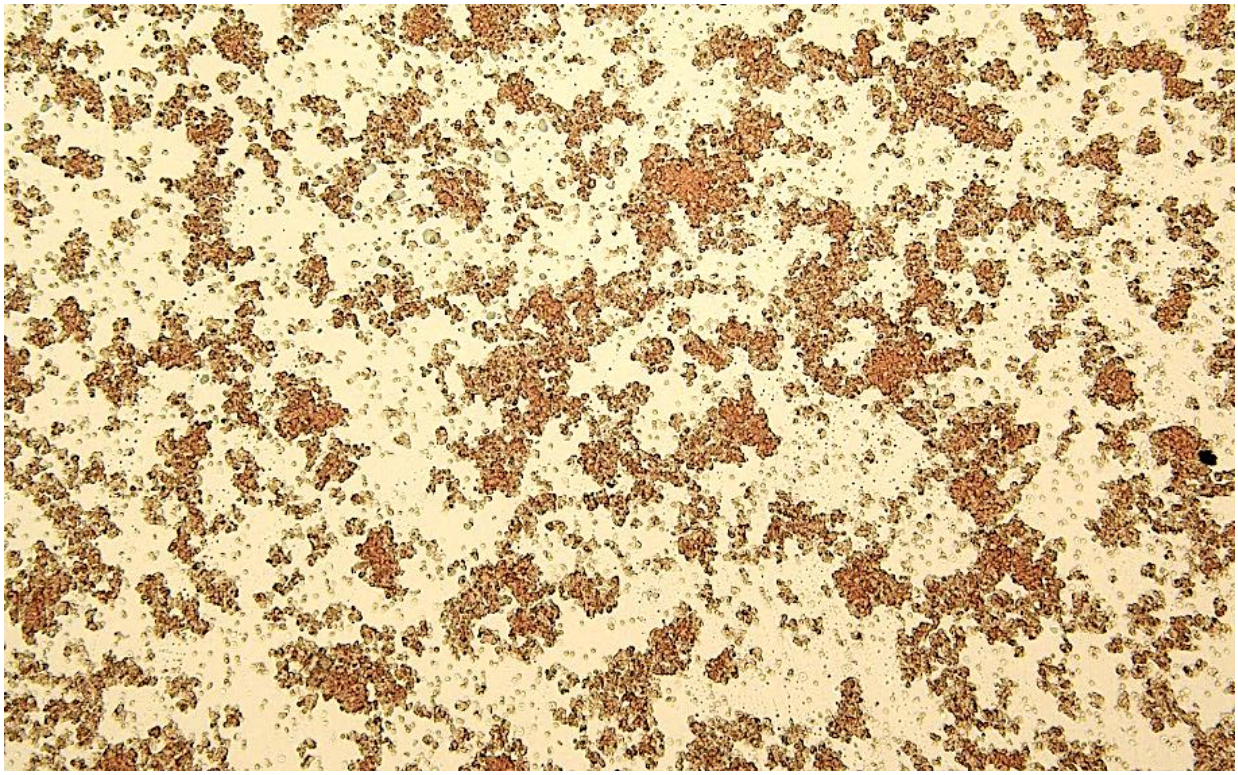

Figure 8 Cold Agglutinin Titration. 1:128 dilution at 4°C.

Cold agglutinins are autoantibodies that function optimally at low temperatures, generally below 37°C. Most are immunoglobulin (Ig) type M proteins recognizing antigens on RBCs and that can activate complement through the classical pathway with ultimate formation of the membrane attack complex (intravascular hemolysis). However, usually IgM detaches from the erythrocyte membrane when the blood returns in the warmer central circulation and only the C3b fraction of the complement persists. C3b is a strong opsonin and may elicit macrophage binding and spherocytes formation (extravascular hemolysis). Despite that, Cold Agglutinin Disease (CAD), compared to other autoimmune hemolytic anemias, is more chronic and indolent, rarely resulting in overt hemolysis.
CAD is a rare condition and historically, in human medicine, has been classified as primary or secondary. Primary CAD is related to the production of monoclonal IgM (due to the presence of B lymphoproliferative diseases) and secondary CAD which is associated with Epstein Barr virus or with *Mycoplasma pneumonia* and atypical bacterial infections. The common trait of these condition is the production of cold agglutinins (IgM and rarely IgG) against RBC surface antigens, namely “i” and “I”. “i” is more abundant on the erythrocytes of newborns and during growth it is almost completely replaced by “I”; “I” is the most common target of CA and it can also be present on leukocytes and platelets.
Human patients with CAD may present with symptoms correlated to hemolysis (icterus, pigmenturia, fatigue), acrocyanosis, Reynaud’s phenomenon and gangrene. Other signs include livedo reticularis (a

cutaneous physical sign characterized by a transient or persistent net-like cyanotic pattern) and signs correlated to the underlying disease.
In human medicine diagnostic criteria include evidence of chronic hemolysis, positive Direct Antiglobulin Test (DAT) and the demonstration of a significant CA titer in plasma, since titers up to 1:64 can be found in people without CAD.
In veterinary medicine literature only single cases or case series in dogs, cats, non-human primates and dolphins are reported. In dogs, CAD has been observed along with inflammatory conditions, lead exposure, absorption of CA through colostrum or deemed idiopathic. A case report describes the transient presence of CA in a dog infected with *Mycoplasma cynos*, similarly to what has been reported in people diagnosed with *Mycoplasma pneumoniae* infections.
In the present case CA was associated with the evidence of a B lymphoproliferative disease, similar to the most common presentation observed in human medicine.
The artifactual changes that we observed in the RBC cytograms, and the RBC indices, are considered the result of agglutinates (couples, triplets etc, of RBC) counted as a single RBC. This presentation is often reported in people with CAD, but it has never been observed in dogs. By contrast, artifactual leukopenia and thrombocytopenia have been described. In the author's opinion this could be the result of the entrapment of leukocytes and platelets in the RBC aggregates or of the action of CA on common antigens on RBC, leukocytes and platelets.
The spurious reticulocytosis has never been reported. This is probably due to the abnormal distribution of the events in the Retic Scatter Absorption and the consequent inability of the analyzer to properly separate the RBCs and to define the regions of low, medium and high absorbance of reticulocytes (compare Fig 1B and Fig 5B).
Some of the results of the tests performed could have been affected by the handling of the samples. It is recommended that samples form patient with suspected CAD should be handled at 37°C from collection to analysis or storage. In the present case it was not possible to maintain such temperature during shipping to the laboratory. Likewise, the DAT test, according to the manufacturer, must be performed at room temperature; unfortunately, this was in contrast with the needs of the diagnostic workup for patients with suspected CAD. Finally, on day 7 the dog was receiving corticosteroids as part of a chemotherapy protocol, and this may have affected some of the results.
The dog started treatment with a CHOP chemotherapeutic treatment, it is in clinical remission for lymphoma and not symptomatic for CAD at the time of writing. Currently, agglutination at room temperature persists but, CBC is being successfully monitored at the local laboratory following the procedure of warming the sample before analysis, with stable results. Total proteins and serum protein electrophoresis will be monitored at the end of the treatment.

In conclusion, the authors demonstrated the presence of CA in a dog with a B lymphoproliferative disease. To the authors' knowledge, despite being the most common presentation in humans, this is the first case of CA associated with a B lymphoproliferative disease in a dog.

References

Gertz MA. Updates on the Diagnosis and Management of Cold Autoimmune Hemolytic Anemia. Hematol Oncol Clin North Am. 2022 Apr;36(2):341-352. doi: 10.1016/j.hoc.2021.11.001. Epub 2022 Mar 11. PMID: 35282954; PMCID: PMC9088174.

Beato Merino MJ, Diago A, Fernández-Flores Á et al. Clinical and Histopathologic Characteristics of the Main Causes of Vascular Occlusion - Part I: Thrombi. Actas Dermosifiliogr (Engl Ed). 2021 Jan;112(1):1-13. doi: 10.1016/j.ad.2020.09.006. Epub 2020 Oct 9. PMID: 33045208; PMCID: PMC7546665.

Ginter K, Ahsan DM, Bizjak M, Krause K, Maurer M, Altrichter S, Terhorst-Molawi D. Cryoglobulins, Cryofibrinogens, and Cold Agglutinins in Cold Urticaria: Literature Review, Retrospective Patient Analysis, and Observational Study in 49 Patients. Front Immunol. 2021 May 25;12:675451. doi: 10.3389/fimmu.2021.675451. PMID: 34113348; PMCID: PMC8186313.

Berentsen S, D'Sa S, Randen U, Małecka A, Vos JMI. Cold Agglutinin Disease: Improved Understanding of Pathogenesis Helps Define Targets for Therapy. Hemato. 2022; 3(4):574-594.

Kamperschroer C, Tartaro K, Goodchild L, Menke C, Artrip A, Pisharath H. Cold Agglutinin Disease in a Rhesus Macaque (Macaca mulatta). Comp Med. 2023 Oct 29;73(5):398-406. doi: 10.30802/AALAS-CM-23-000025. PMID: 38087406; PMCID: PMC10702163.

Lahav M, Rosenberg I, Wysenbeek AJ. Steroid-responsive idiopathic cold agglutinin disease: a case report. Acta Haematol. 1989;81(3):166-8. doi: 10.1159/000205552. PMID: 2496566.

Rojas-Temahuay G, Crain S, Benson C, Sharkey L, Nothnagel G. Cold agglutinin activity in 2 dogs. Vet Clin Pathol. 2014 Sep;43(3):330-6. doi: 10.1111/vcp.12173. Epub 2014 Jul 23. PMID: 25056251.

Pinkos AC, Friedrichs KR, Monaghan KN, Sample SH, Trepanier LA. Transient cold agglutinins associated with Mycoplasma cynos pneumonia in a

dog. Vet Clin Pathol. 2015 Dec;44(4):498-502. doi: 10.1111/vcp.12286. Epub 2015 Sep 10. PMID: 26356600.

Takubo K, Shirakata C. A case of cold agglutinin disease in a bottlenose dolphin (Tursiops truncatus). J Vet Med Sci. 2023 Nov 18;85(11):1245-1251. doi: 10.1292/jvms.23-0037. Epub 2023 Oct 2. PMID: 37779092; PMCID: PMC10686766.

Greene CE, Kristensen F, Hoff EJ, Wiggins MD. Cold hemagglutinin disease in a dog. J Am Vet Med Assoc. 1977 Mar 1;170(5):505-10. PMID: 845080.