Unraveling the mystery of discrepancies between two hematology analyzers for thrombocytosis and leukocytosis in a dog

Contributors

Javier Martínez-Caro[1], Beatriz Agulla[1], Alba Benet[2], Josep Pastor[1]

[1]Servei d'Hematologia Clínica Veterinària, Departament de Medicina i Cirurgia Animals, Facultat de Veterinària, Universitat Autònoma de Barcelona, Bellaterra, Barcelona, Spain.
[2]Pratdesaba Veterinaris Malla, Malla, Barcelona, Spain.

Javier Martínez-Caro – Javier.Martinez.Caro@uab.cat

Specimen

EDTA whole blood, blood smear, heparin plasma, serum, liver and spleen fine needle aspiration cytology.

Signalment

6-year-old, intact male, English bulldog.

History

After a period of generalized weakness and sporadic vomiting, the dog was brought to the veterinary center for evaluation. The dog was up to date on vaccinations and deworming.

Clinical findings

General physical examination of the animal revealed no significant abnormalities. On ophthalmological examination, bilateral corneal edema, a single corneal ulcer (positive fluorescein test), normal intraocular pressure, and decreased Schirmer's test (<15 mm/minute in both eyes) were found.

A complete blood cell count (CBC) was performed at the veterinary clinic, on a point-of-care test system, the Urit Smart V5 (URIT Medical Electronic Group, Guilin, Guangxi China), and repeated 24 hours later on a Sysmex XN-1000V (Sysmex Corporation, Norderstedt, Germany) with peripheral blood smear examination. The CBC results of both analyzers are shown in **Table 1** and representative histograms and scattergrams of both analyzers are presented in **Table 2**. Blood smear microphotographs are shown in **Figure 1**. Heparin plasma clinical chemistry was performed on a VetScan VS2 (Zoetis, Parsippany, NJ, USA); relevant abnormalities included: elevated total protein (11.8 g/dL [reference interval {RI}: 5.4-8.2 g/dL]), globulins (9.6 g/dL [RI: 2.3-5.2 g/dL]), and decreased albumin (2.2 g/dL [RI: 2.5-4.4 g/dL]).

A rapid immunochromatographic test (Uranotest Quattro, Uranovet, Spain) was performed to screen for vector-borne infections (for the detection of *Erlichia canis*, *Anaplasma* spp. [*A. platys* and *A. phagocytophilum*] and *Leishmania infantum* antibodies, and *Dirofilaria immitis* antigens), which gave an uncertain/suspicious positive result for *L. infantum*. Serum protein electrophoresis (SPE) and serology (ELISA) for *Leishmania* spp. were sent to an external laboratory for analysis. The SPE was performed on a CAPILLARYS 3 TERA (Sebia, Lisses, France), and the results are presented in **Table 3**. The ELISA for *Leishmania* spp. was negative.

A radiographic investigation of the thorax and abdomen revealed no significant findings. Mild splenomegaly was noted on abdominal ultrasound. Based on previous findings, a fine needle aspirate biopsies of the spleen and liver were performed, and the cytologic specimens were reviewed. The **Figure 2** illustrates the most relevant cytologic findings of the spleen.

Table 1: Complete blood cell count performed on the Urit Smart V5 and the Sysmex XN-1000V. Right column: manual packed cell volume (PCV) and white blood cell differential based on peripheral blood smear examination.

Parameter (units):	Result of Urit Smart V5	Reference interval (Urit)	Result of Sysmex XN-1000V	Reference interval (Sysmex)	Manual data
Red blood cell count (10^{12} cells/L)	**3.45**	*5.1-8.5*	**3.41**	*5.5-8.5*	–
Hematocrit (%)	**24.3**	*36-56*	**25.3**	*37-55*	PCV: **25%**
Hemoglobin (g/L)	**10.2**	*11-21*	**10.1**	*12-18*	–
Mean cell volume (fL)	70.7	*62-78*	74.2	*62-77*	–
Mean cell hemoglobin (pg)	**29.5**	*21-28*	**29.6**	*21.5-26.5*	–
Mean cell hemoglobin concentration (g/dL)	**41.9**	*30-38*	**39.9**	*33-37*	–
Reticulocyte count (10^9 cells/L)	–	–	**110**	*0-60*	–
Reticulocyte-Hemoglobin (RET-He; pg)	–	–	28.6	*>20.9*	–
White blood cell count (10^9 cells/L)	**95.36**	*6-17*	**5.26**	*6-17*	(5.26)
Neutrophils (10^9 cells/L)	**11.68**	*3.6-11.3*	**2.87**	*3-11.5*	(63%) 3.3
Lymphocytes (10^9 cells/L)	**66.51**	*0.8-4.7*	1.77	*1-4.8*	(25%) 1.3
Monocytes (10^9 cells/L)	**15.87**	*0.14-1.97*	0.58	*0.15-1.35*	(12%) 0.6
Eosinophils (10^9 cells/L)	0.97	*0.04-1.56*	–	*0.1-1.5*	(0%) 0
Basophils (10^9 cells/L)	**0.32**	*0-0.12*	0.04	*0-0.2*	(0%) 0
Platelets [impedance] (10^9 cells/L)	**1379**	*117-460*	**945**	*200-500*	–
Platelets [optical – RET channel] (10^9 cells/L)	–	–	**1619**	*200-500*	–
Platelets [optical – PLT-F channel] (10^9 cells/L)	–	–	**126**	*200-500*	–
Plateletcrit (%)	1.2	*0-2.9*	**0.9**	*0.14-0.61*	–
Mean platelet volume (fL)	9	*5-15*	9.6	*9-12.7*	–
Immature platelets (10^9 cells/L)	–	–	23	*1.7-25.6*	–
Immature platelet fraction (%)	–	–	**18**	*1.2-10.4*	–

Table 2: Hematology analyzer graph representations. From Urit Smart V5: A) platelet impedance histogram, and B) scattergram from WDF channel. From Sysmex XN-1000V: C) platelet impedance histogram (PLT-I), D) platelet scattergram from RET channel (PLT-O), E) platelet scattergram from PLT-F channel (PLT-F), F) scattergram from WDF channel, and G) scattergram from WNR channel. Left column: healthy control dog; right column: dog from this case. Abbreviations: fL, femtoliter; FSC, forward scatter; S0, forward scatter; S90, side scatter; SFL, side fluorescence light; SSC, side scatter. Particle representation: in WDF channel of Urit, green dots (lymphocytes), pink dots (monocytes), blue dots (neutrophils), and red dots (eosinophils); in RET channel, clear blue dots (platelets); in PLT-F channel, clear blue dots (mature platelets), green dots (immature platelets); in WDF channel of Sysmex, clear blue dots (neutrophils), purple dots (lymphocytes), green dots (monocytes), and red dots (eosinophils); in WNR channel, clear blue dots (white blood cells [except basophils]), purple dots (nucleated red blood cells), yellow dots (basophils).

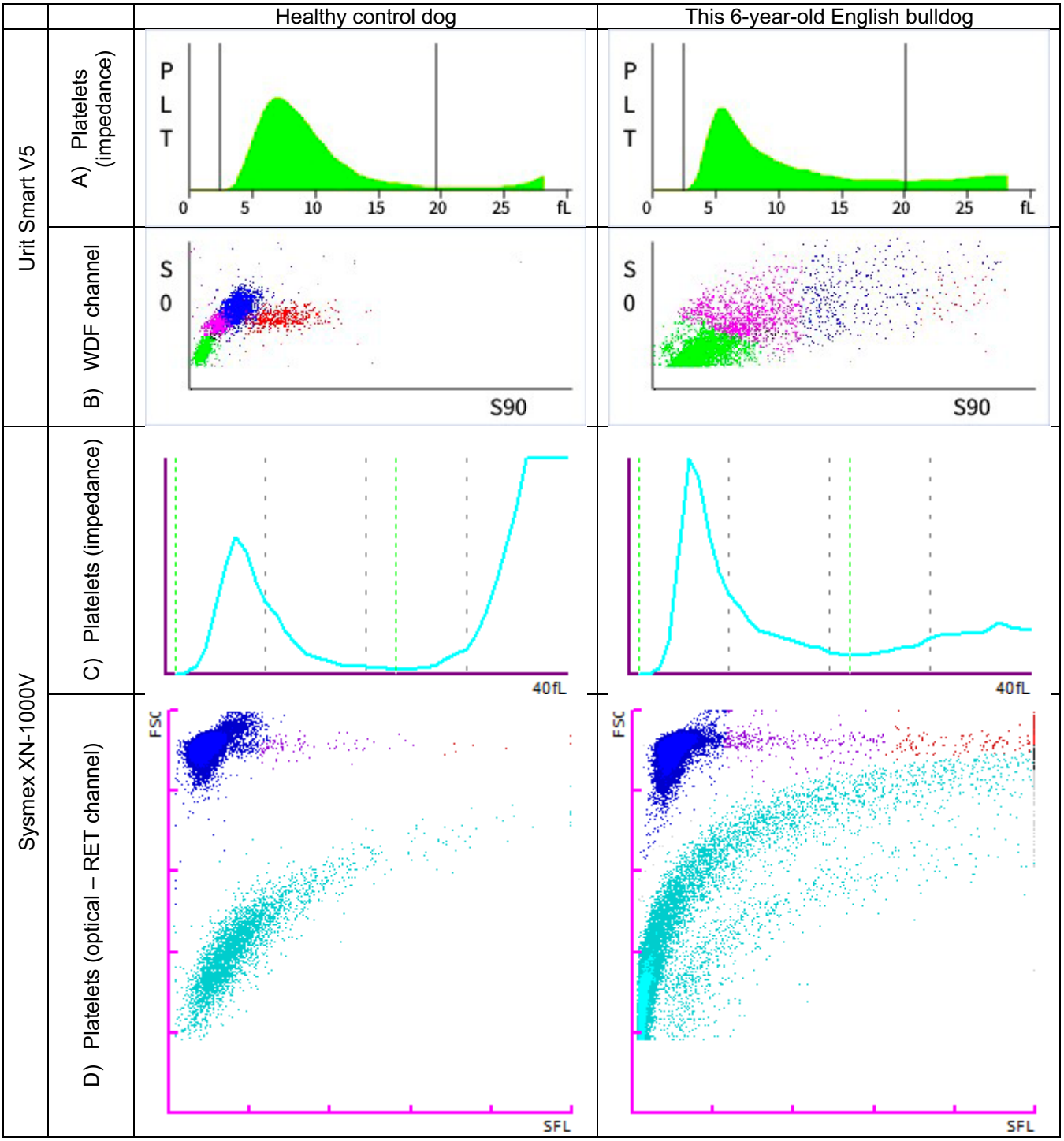

Sysmex XN-1000V
E) Platelets (optical – PLT-F channel)
F) WDF channel
G) WNR channel
FSC
SFL
SSC

Figure 1: Peripheral blood smear micrographs. Modified Wright stain, original magnification ×20, ×63, ×63, and ×100 objectives, respectively.

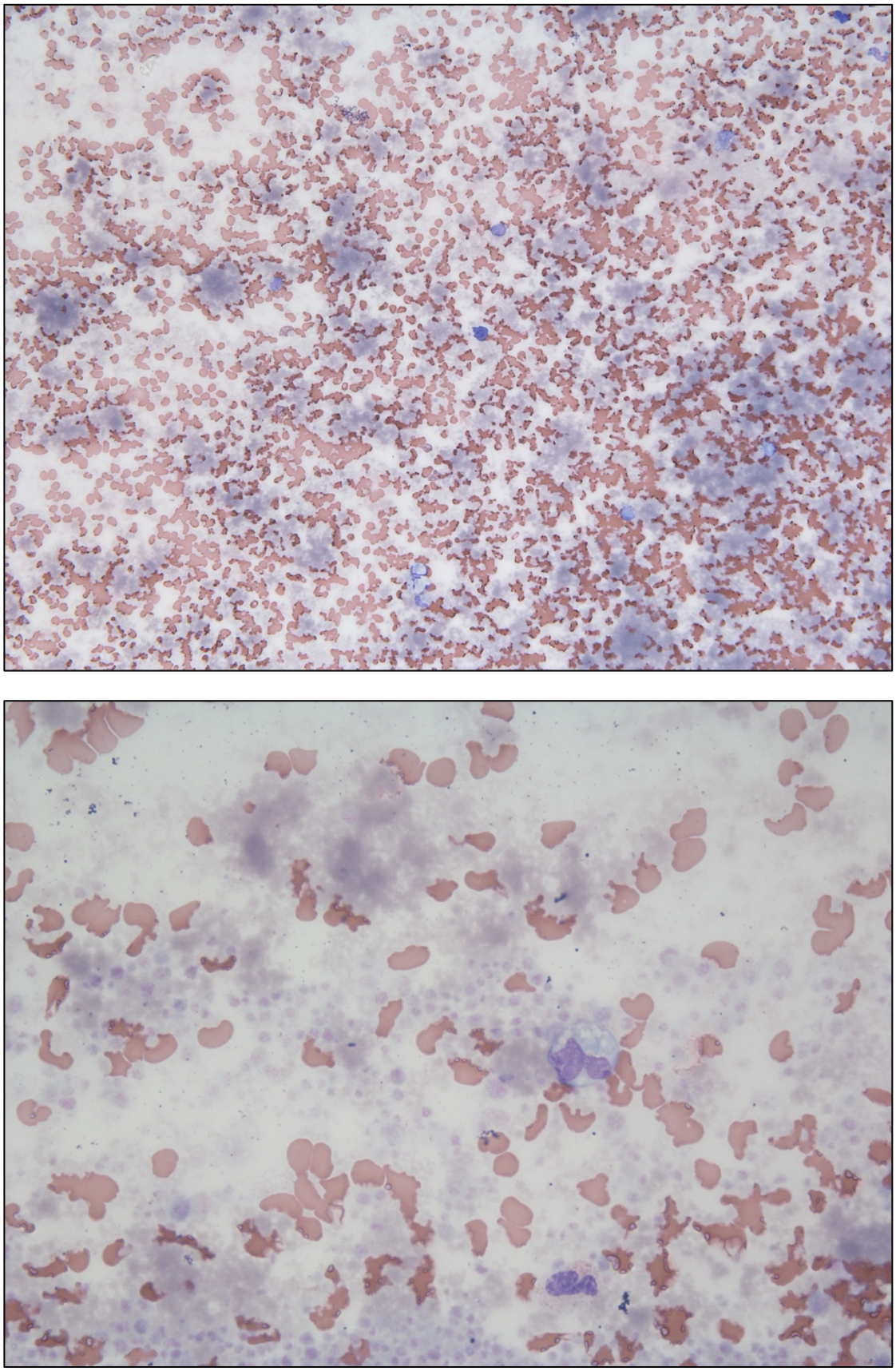

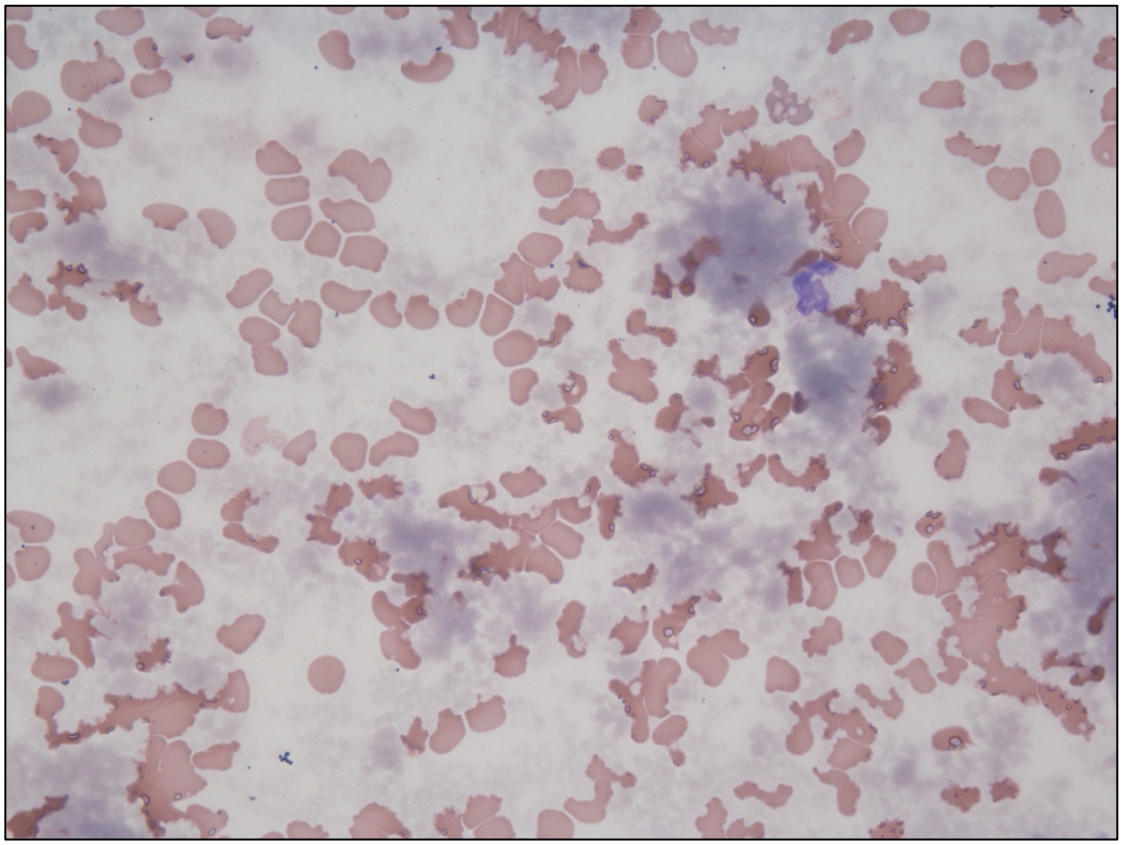

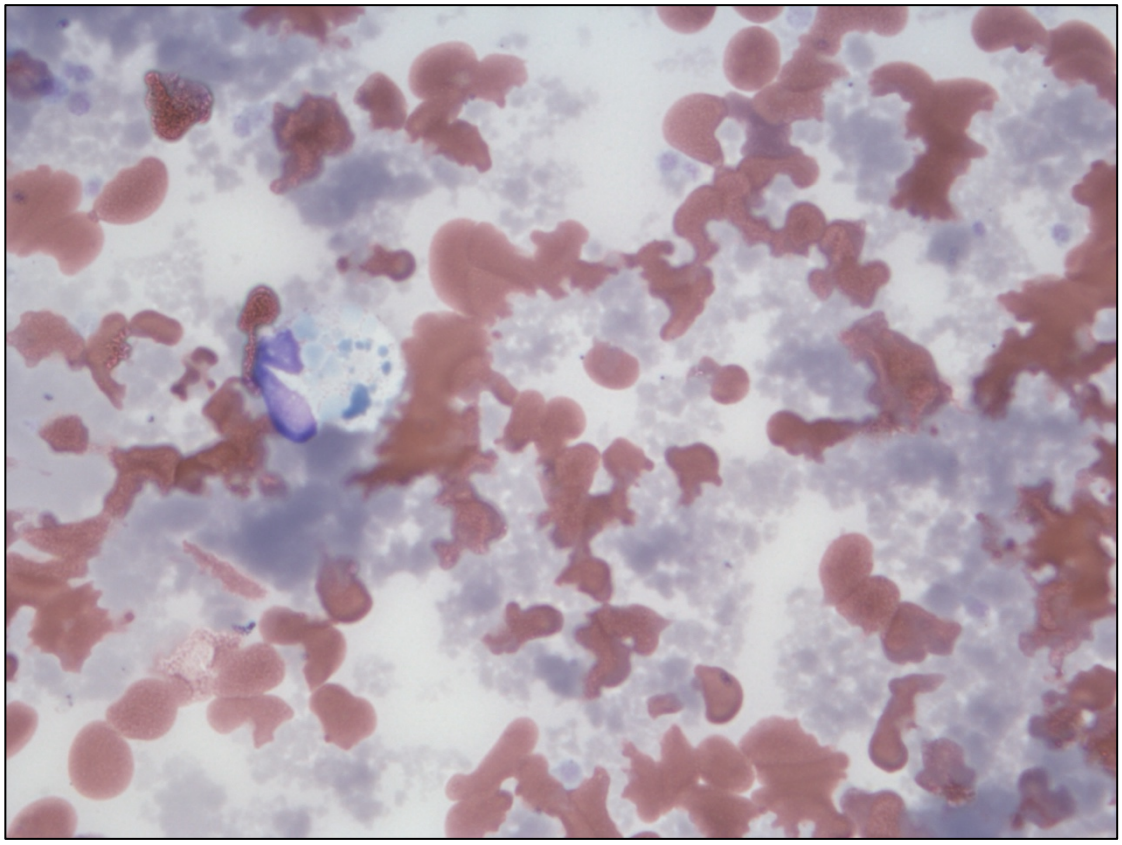

Table 3: Serum protein electrophoresis: absolute concentrations, densitometer tracing of this animal and densitometer tracing from a healthy control dog. Bolded values are outside the reference interval.

Parameter (units):	Result	Reference interval
Total protein (g/L)	**138**	*47-68*
Albumin (g/L)	**24.3**	*25-40*
Total globulin (g/L)	**113.8**	*15-35*
Alfa-1–globulin (g/L)	4	*3-7*
Alfa-2–globulin (g/L)	10.9	*3-11*
Beta–globulin (g/L)	**17.3**	*8-14*
Gamma–globulin (g/L)	**81.6**	*7-16*
Albumin:globulin ratio	**0.21**	*0.5-1.1*

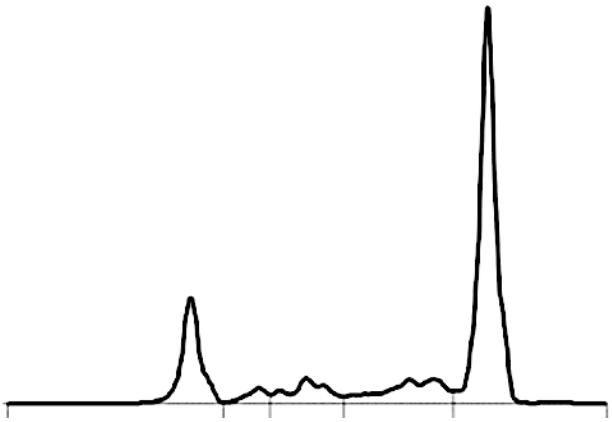

SPE from this animal

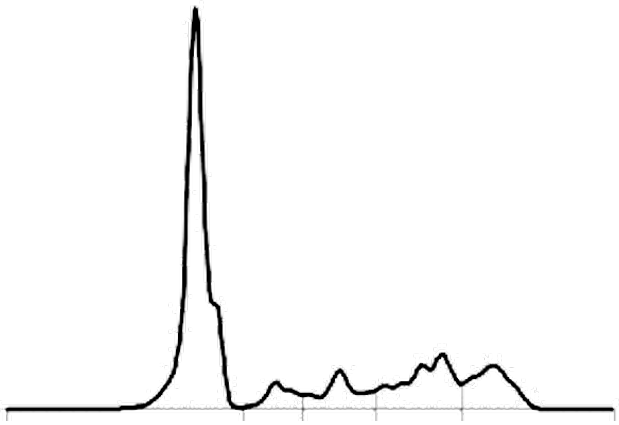

Normal SPE from a healthy control dog

Figure 2: Cytological micrographs of the FNA of the spleen. Aqueous Romanowsky stain, ×40, ×63, ×63, and ×100 objectives, respectively.

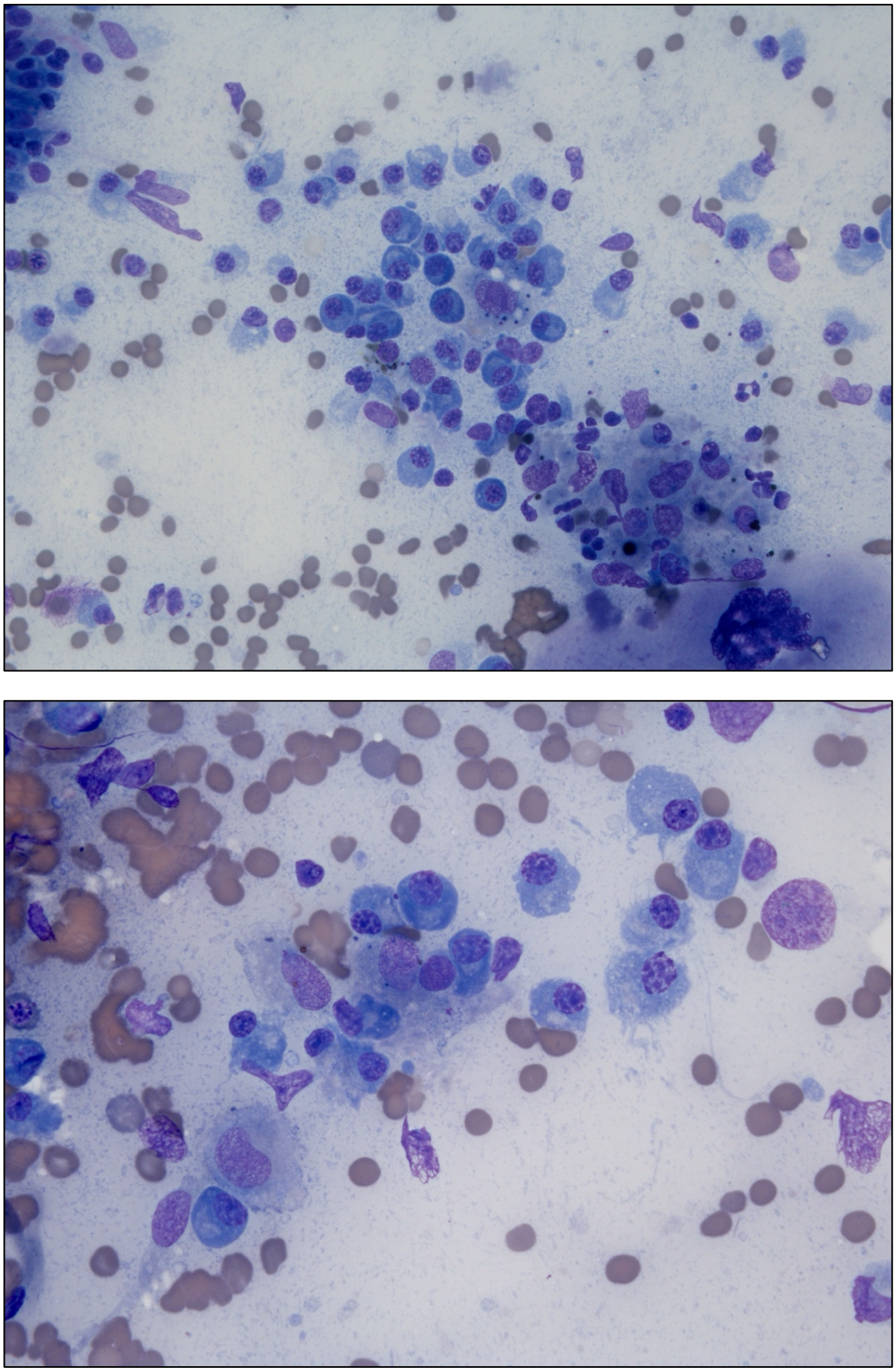

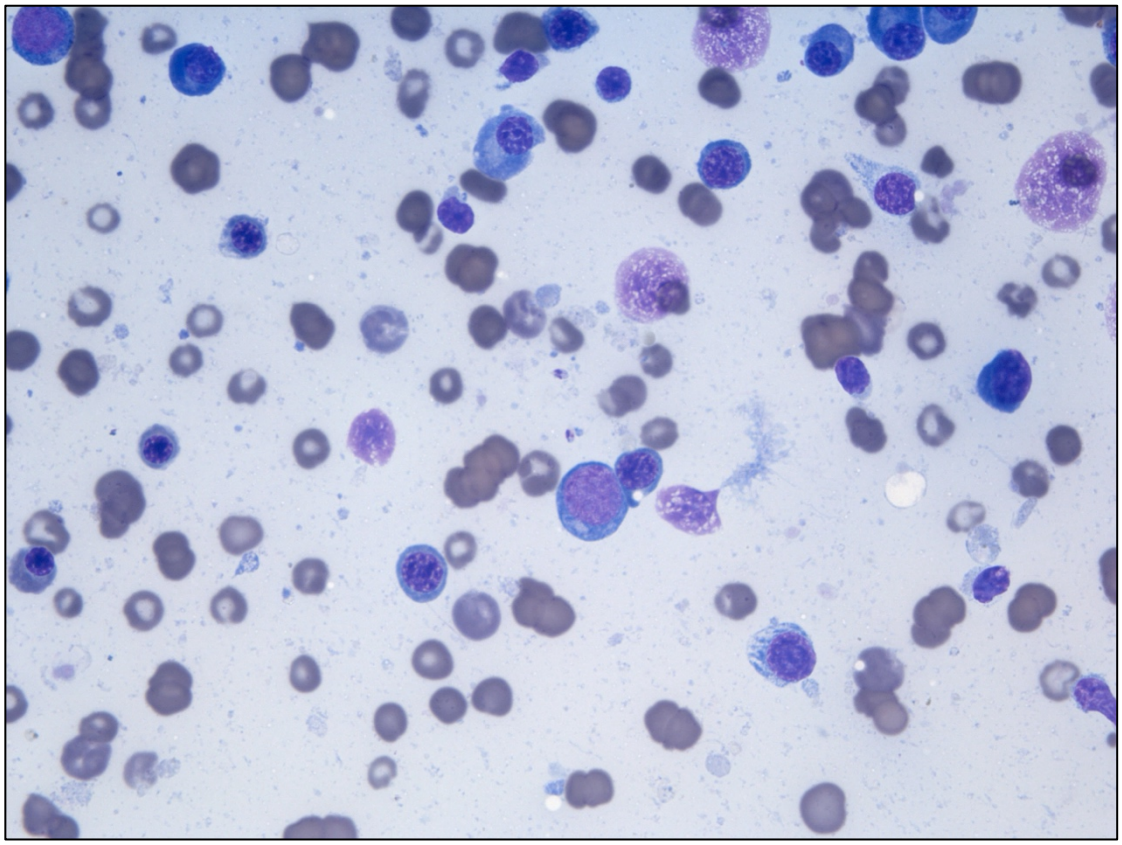

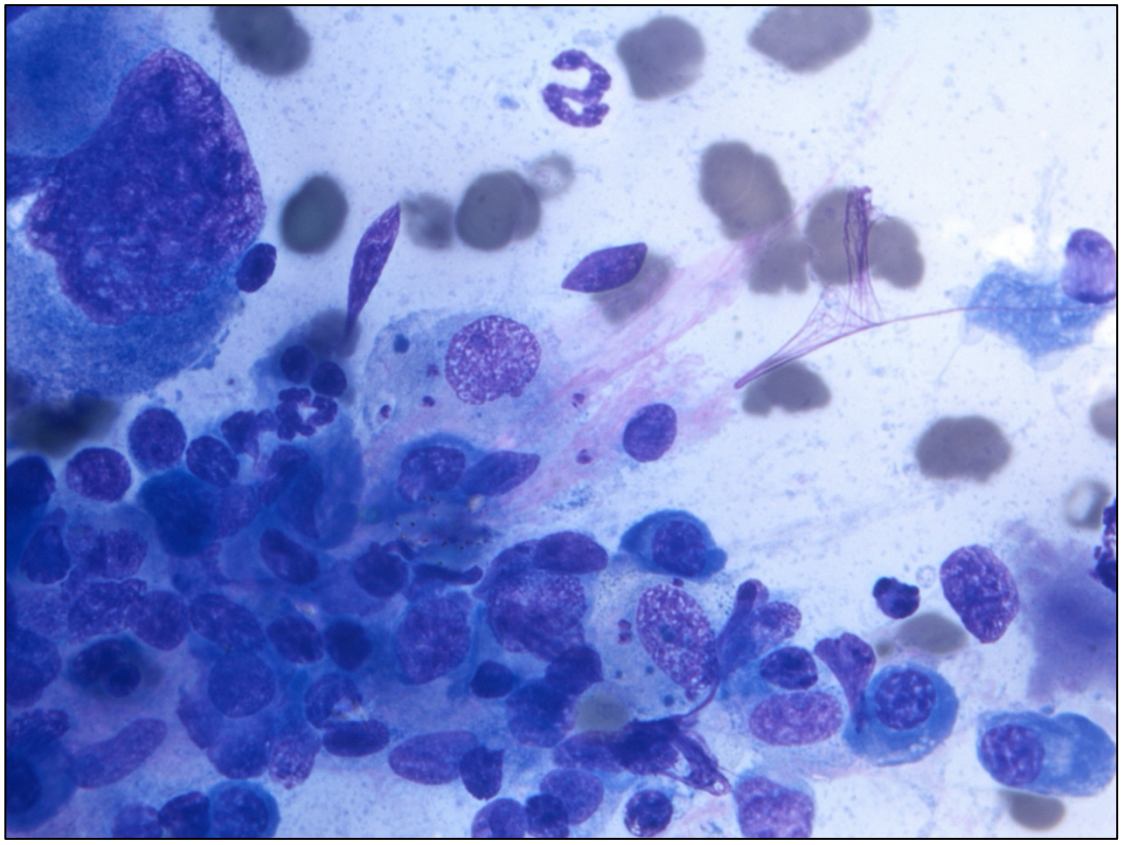

Questions

1) Which are the main discrepancies between the CBC results from the two hematology analyzers?

2) What morphologic abnormalities are seen in the peripheral blood smear?

3) Based on all the information provided:
    a. What is your interpretation?
    b. How could the hematological discrepancies be explained?
    c. What further tests/analysis would you recommend to prove this condition?

Interpretation/Diagnosis

-Global interpretation: visceral leishmaniosis with monoclonal hypergammaglobulinemia and cryoglobulinemia.

-Hematology:

-Abundant protein aggregates/precipitates most consistent with cryoglobulins.
-Moderate, normocytic, normochromic, mildly regenerative, anemia, with appropriate rubricytosis. Probable *in vitro* erythrocyte fragmentation (poikilocytosis, acanthocytosis, schistocytosis).
-Mild leukopenia. Leukocyte phagocytosis of protein deposits.
-Aggregated platelets (possible mild thrombocytopenia or normal count).

-Clinical chemistry: marked hyperproteinemia with mild hypoalbuminemia and monoclonal marked hypergammaglobulinemia.

-Spleen cytology: *Leishmania infantum* infection, plasma cell hyperplasia and extramedullary hematopoiesis.

Additional information

To demonstrate the presence of cryoglobulins, blood at room temperature was centrifuged in a capillary tube, see **Figure 3**. A significant precipitate fraction was observed, and interpreted as cryoglobulin precipitate (45% of all capillary volume, 60% of the plasma fraction).

Additionally, the blood was reanalyzed soon after warming to 37°C on a Sysmex XN-1000V. The CBC results and graphical histograms and scattergrams are presented in **Table 4** and **Table 5**, respectively. The interference caused by cryoglobulin precipitates in the platelet determination by impedance and optically in the RET channel has been corrected and improved, respectively. The optical platelet determination based on the PLT-F channel was not affected by cryoglobulins at either 37°C or at room temperature. In the WDF channel, cryoglobulins caused interference that invalidated the eosinophil count at room temperature. This issue was resolved by analyzing the blood after it was warmed to 37°C.

A blood smear was prepared soon after warming blood to 37°C, micrographs showed in **Figure 4**. The viscosity of the blood decreased significantly compared to the previous blood smear prepared with the sample at room temperature. Large cryoglobulin precipitates almost completely disappeared on this new blood smear. The background was markedly proteinaceous, with granular to amorphous bluish to grayish material, homogeneously distributed throughout the slide.

Figure 3: Photograph of a capillary tube centrifuged with blood at room temperature showing cryoglobulin precipitate. Abbreviation: packed cell volume (PCV).



Table 4: Complete blood cell count performed on Sysmex XN-1000V with blood at room temperature and blood warmed to 37°C. Right column: manual packed cell volume (PCV) and white blood cell differential based on peripheral blood smear examination. Bolded values are outside the reference interval.

Parameter (units):	Blood analysis at room temperature	Blood analysis after warming to 37°C	Reference interval (Sysmex)	Manual data
Red blood cell count (10^{12} cells/L)	**3.41**	**3.05**	*5.5-8.5*	–
Hematocrit (%)	**25.3**	**23.6**	*37-55*	PCV: **25%**
Hemoglobin (g/L)	**10.1**	**8.6**	*12-18*	–
Mean cell volume (fL)	74.2	**77.4**	*62-77*	–
Mean cell hemoglobin (pg)	**29.6**	**28.2**	*21.5-26.5*	–
Mean cell hemoglobin concentration (g/dL)	**39.9**	36.1	*33-37*	–
Reticulocyte count (10^9 cells/L)	**110**	59.2	*0-60*	–
Reticulocyte-Hemoglobin (RET-He; pg)	28.6	26.1	*>20.9*	–
White blood cell count (10^9 cells/L)	**5.26**	**4.41**	*6-17*	(5.26)
Neutrophils (10^9 cells/L)	**2.87**	**1.62**	*3-11.5*	(63%) 3.3
Lymphocytes (10^9 cells/L)	1.77	2	*1-4.8*	(25%) 1.3
Monocytes (10^9 cells/L)	0.58	0.73	*0.15-1.35*	(12%) 0.6
Eosinophils (10^9 cells/L)	–	0.03	*0.1-1.5*	(0%) 0
Basophils (10^9 cells/L)	0.04	0.03	*0-0.2*	(0%) 0
Platelets [impedance] (10^9 cells/L)	**945**	**134**	*200-500*	–
Platelets [optical – RET channel] (10^9 cells/L)	**1619**	**530**	*200-500*	–
Platelets [optical – PLT-F channel] (10^9 cells/L)	**126**	**101**	*200-500*	–
Plateletcrit (%)	**0.9**	**0.11**	*0.14-0.61*	–
Mean platelet volume (fL)	9.6	**8.5**	*9-12.7*	–
Immature platelets (10^9 cells/L)	23	20.3	*1.7-25.6*	–
Immature platelet fraction (%)	**18**	**20.1**	*1.2-10.4*	–

Table 5: Sysmex XN-1000V generated representations of: A) platelet impedance histogram (PLT-I), B) platelet scattergram from RET channel (PLT-O), C) platelet scattergram from PLT-F channel (PLT-F), D) scattergram from WDF channel, and E) scattergram from WNR channel. Left column: healthy control dog blood analyzed at room temperature; central column: blood from this case analyzed at room temperature; right column: blood from this case analyzed after warming to 37°C. Abbreviations: fL, femtoliter; FSC, forward scatter; SFL, side fluorescence light; SSC, side scatter. Particle representation: in RET channel, clear blue dots (platelets); in PLT-F channel, clear blue dots (mature platelets), green dots (immature platelets); in WDF channel, clear blue dots (neutrophils), purple dots (lymphocytes), green dots (monocytes), and red dots (eosinophils); in WNR channel, clear blue dots (white blood cells [except basophils]), purple dots (nucleated red blood cells), yellow dots (basophils).

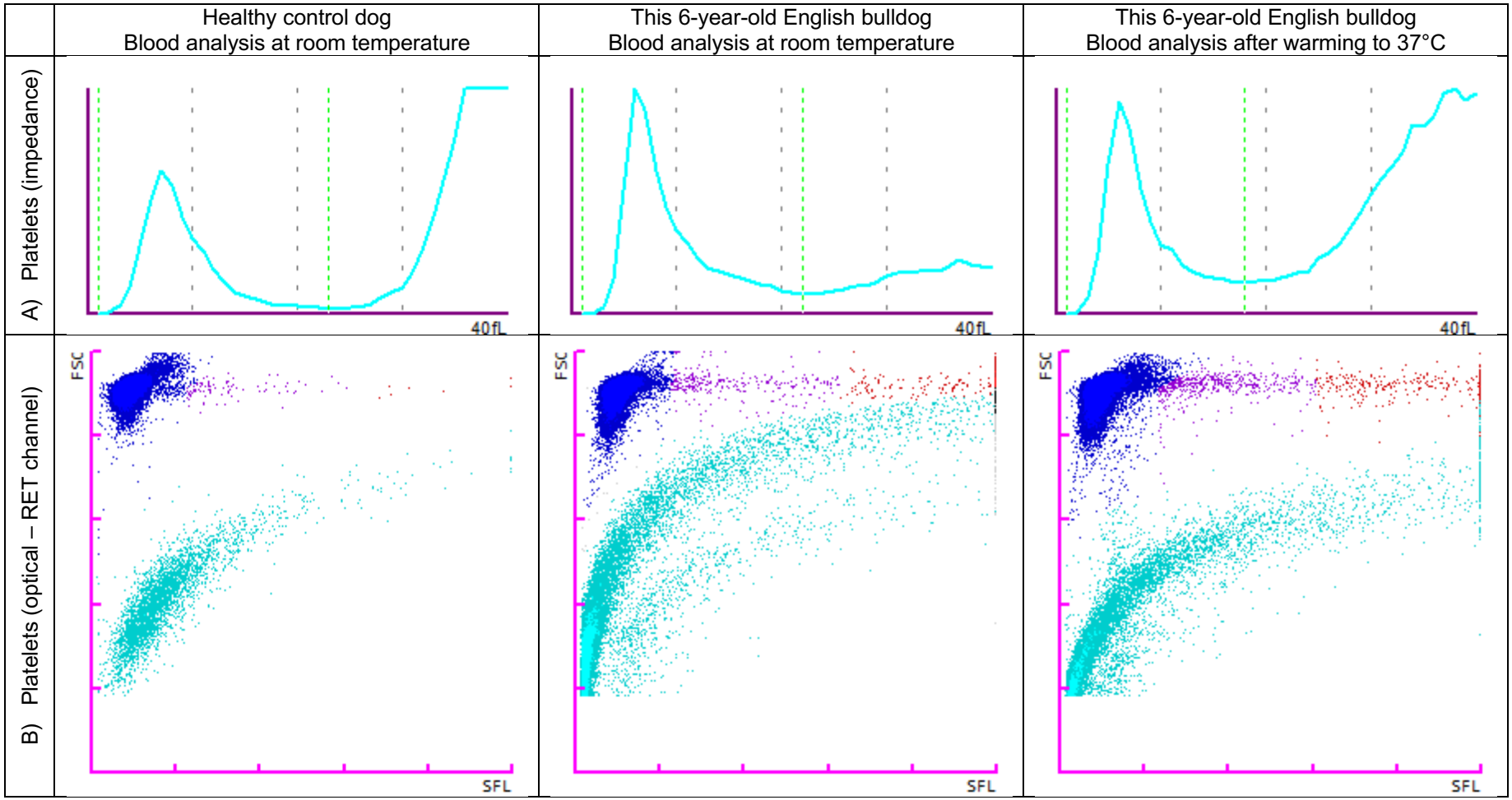

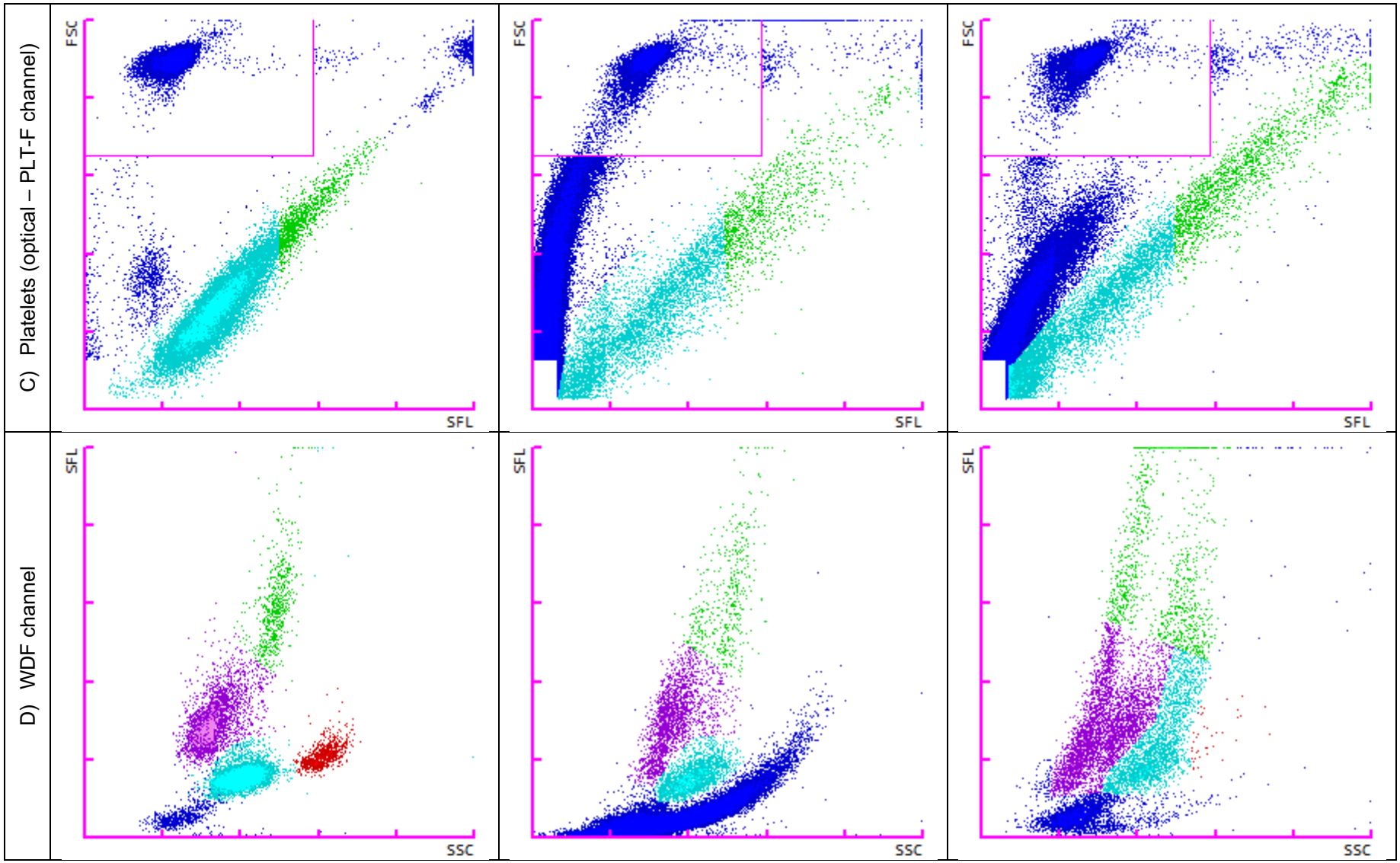
C) Platelets (optical – PLT-F channel)
D) WDF channel
FSC
SFL
SSC

E) WNR channel

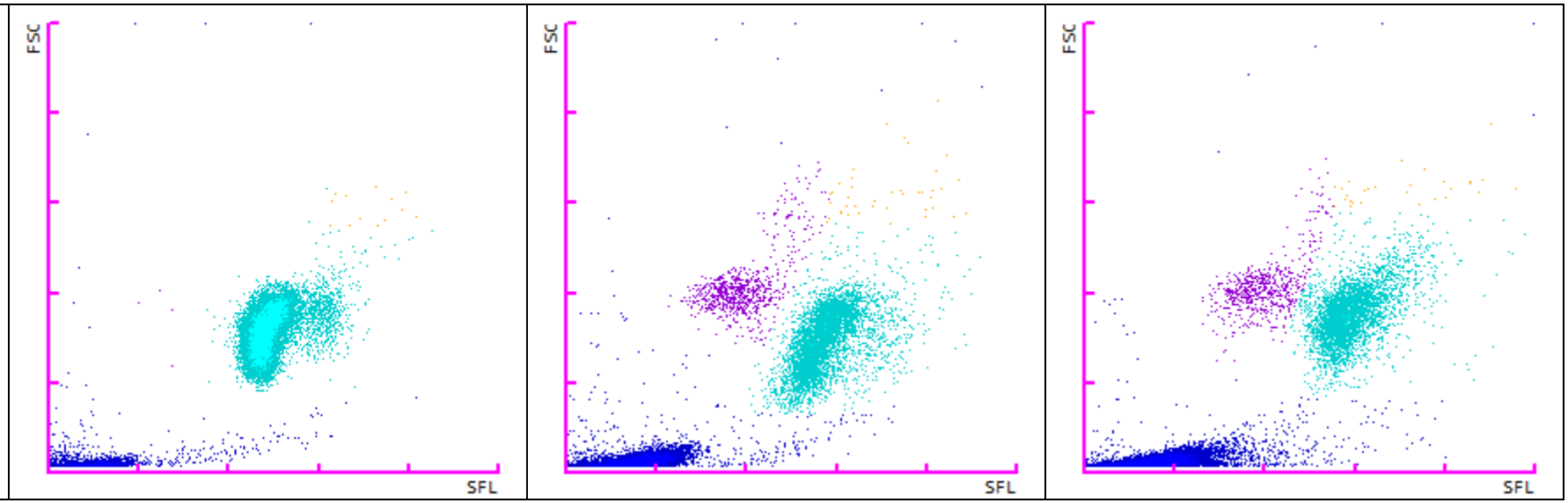

Figure 4: Peripheral blood smear micrographs. Smear prepared after warming to 37°C. Modified Wright stain, original magnification ×20, ×63, ×63, and ×100 objectives, respectively.

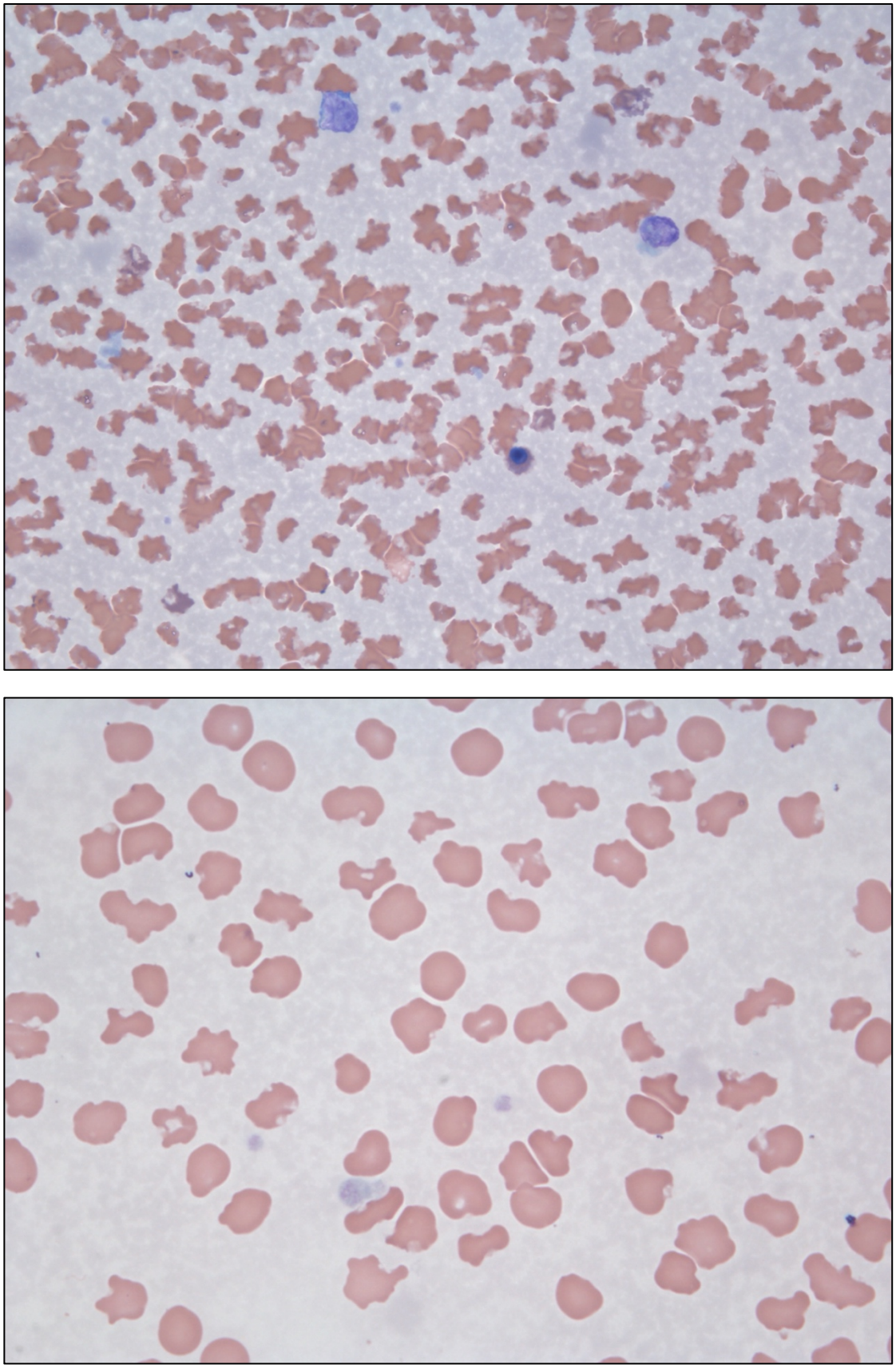

Follow up and clinical outcome

Ocular treatment was administered at time of the first visit: polymyxin B sulfate, neomycin sulfate, gramicidin (Oftalmowell, Teofarma Srl, Pavia, Italy), diclofenac sodium (Voltaren, Laboratoires THEA, Clermont-Ferrand France), and lubricant gel (Lubrithal Gel, Dechra Veterinary Products, Barcelona, Spain). Once the corneal ulcer has been resolved, treatment for keratoconjunctivitis sicca will be initiated. The administration of allopurinol, meglumine antimoniate, and glucocorticoids (at anti-inflammatory dosing) will commence upon the consent of the dog's owner for the treatment of canine leishmaniosis.

Answers to questions

1) *Which are the main discrepancies between the CBC results from the two hematology analyzers?*

The largest discrepancy between the two analyzers was seen in the total white blood cell (WBC) count. The Urit Smart V5 reported a total WBC count of 95.36 × 10^9 cells/L (extreme leukocytosis), while the Sysmex XN-1000V reported a count of 5.26 × 10^9 cells/L (mild leukopenia). Based on the additional information presented and the correlation with the peripheral blood smear, the latter count appears to be more accurate. The automated WBC differential also differs between the analyzers.
The platelet count calculated by impedance on the Urit Smart V5 (1379 × 10^9 cells/L) was not significantly different from the impedance (945 × 10^9 cells/L) and the optical RET channel (1619 × 10^9 cells/L) on the Sysmex XN-1000V. However, it was significantly different from the optical PLT-F channel (126 × 10^9 cells/L) on the Sysmex XN-1000V, which appears to be the closest to the true platelet concentration (platelets were aggregated and no accurate estimate was possible, but was subjectively interpreted as possible mild thrombocytopenia or normal count).
No significant discrepancies were found with respect to erythron.

2) *What morphologic abnormalities are seen in the peripheral blood smear?*

There was a very abundant proteinaceous material, homogeneously distributed, bluish to grayish, amorphous to globular, compatible with protein precipitates/aggregates. This material was interpreted to be cryoglobulins.
Red blood cell (RBC) showed a marked poikilocytosis, mainly due to marked acanthocytosis and schistocytosis. In the context of this case, this was interpreted as probable *in vitro* RBC fragmentation.
Most of the leukocytes appeared to be poorly preserved. There were activated macrophages, and both neutrophils and macrophages with phagocytized proteinaceous bluish material.
There were frequent platelet aggregates on the feathered edge, which were morphologically distinguishable from protein precipitates.

3) *Based on all the information provided:*
   a. *What is your interpretation?*

See "Interpretation/Diagnosis" section above.

   b. *How could the hematological discrepancies be explained?*

The falsely elevated WBC (pseudoleukocytosis) observed on Urit Smart V5 and platelets (pseudothrombocytosis) observed on both analyzers were attributed to the detection of precipitates of cryoglobulins by the analyzers, which resulted in misclassification as WBC and platelets, respectively. The cryoprecipitates directly interfered with some parameters measured by impedance (platelet in both analyzers) and some parameters measured by optical technology (total WBC count on Urit Smart V5, all cells in the WBC differential of Urit Smart V5, eosinophils in the WBC differential of Sysmex XN-1000V, platelets in the RET channel of Sysmex XN-1000V).

   c. *What further tests/analysis would you recommend to prove this condition?*

In order to demonstrate the presence of cryoglobulins, it could be useful: A) centrifugation of the blood in a capillary tube to identify cryoglobulin precipitate, and B) reanalysis of the whole blood after warming it to 37°C to ascertain whether the falsely increased values (WBC and platelets) correct.

Discussion

Cryoglobulinemia is the presence of cryoglobulins in the blood, which are abnormal immunoglobulins (Ig) that precipitate at low temperatures (less than 37°C) and dissolve again after rewarming.[1] The simplest way to confirm cryoglobulins is to show that there's protein precipitation or gelation at a temperature below 37°C (i.e., centrifugation in a capillary tube to identify visible cryoglobulin precipitate) and that this material dissolves after reheating to 37°C (i.e., reanalysis of the warmed sample should correct the false alterations on automated hematology).[2] Cryoglobulinemia is very rare in veterinary medicine, and to the authors'

knowledge, peer reviewed reports in dogs are limited to four cases with multiple myeloma[3–6] and two cases with Waldenström's macroglobulinemia.[3,7]

In human medicine, the Brouet's classification is used for distinguishing different types of cryoglobulinemia. Type I cryoglobulinemia is composed of a single monoclonal Ig, usually an IgM or IgG (simple type cryoglobulinemia). Type II cryoglobulinemia is characterized by immune complexes formed by polyclonal Ig and one or more monoclonal Ig, typically monoclonal IgM and polyclonal IgG (mixed monoclonal cryoglobulinemia). Type III cryoglobulinemia involves only polyclonal Ig (mixed cryoglobulinemia). The most common cause of type I cryoglobulinemia is B-cell neoplasia (i.e., multiple myeloma, Waldenström's macroglobulinemia). Mixed cryoglobulinemia (types II and III) is usually due to an infectious cause, primarily hepatitis C virus infection (70% to 90% of the cases). Many other causes can cause types II and III cryoglobulinemia, including other infections, B-cell lymphoid malignancies, and autoimmune diseases.[1]

In this case, the SPE revealed a monoclonal gammopathy involving the gamma globulin region. However, the nature of our monoclonal gammopathy has not been studied further. Immunofixation could be of value in order to further classify this anomaly. Considering the *Leishmania infantum* infection in this dog, type II cryoglobulinemia is suspected, but a type I should also be considered, especially considering that a plasma cell tumor involving the spleen cannot be completely ruled out due to the increased plasma cell population. A new spleen cytology after treatment for leishmaniasis may help to demonstrate a possible concurrent plasma cell tumor.

There are scant human reports of cryoglobulinemia (type III) secondary to *Leishmania infantum* infection.[8] It has been hypothesized that some circulating immune complexes in cases of canine leishmaniosis may include cryoglobulins, and this may contribute to some clinical signs.[9] However, to our knowledge, this is the first report of *Leishmania infantum* associated cryoglobulinemia occurring in dogs.

Although most cases of monoclonal gammopathies are associated with neoplastic conditions (B-cell neoplasia), a significant proportion of dogs with this laboratorial abnormality are caused by an infectious etiology, mainly leishmaniosis (3/18 cases) and ehrlichiosis (2/18).[3] It is also described that few (3/31 cases) dogs with *Leishmania infantum* may result in clonal rearrangement in PCR for antigen receptor rearrangement (PARR) test. However, none of the cases of this study showed monoclonal gammopathy.[10]

The negative result of the ELISA against *Leishmania* spp. was attributed to the cryoglobulin precipitation, since it has been described that cryoprecipitates may disrupt the measurement of specific Ig through techniques such as immunofluorescence and ELISA.[11]

In human medicine, the most common ocular manifestation of cryoglobulinemic vasculitis is keratoconjunctivitis sicca, which occurs in 43% of the cases with ocular involvement. This is somewhat expected, given that most of these cases were hepatitis C virus positive, and it is well known that between 10% and 67% of hepatitis C virus infected patients suffer from dry eye disease, with or without cryoglobulinemia.[12] On the other hand, the prevalence of keratoconjunctivitis sicca in dogs suffering from leishmaniosis with ocular signs ranges from 2.8% to 26.8%.[13,14] The proposed pathogenic mechanisms of dry eye syndrome in dogs with leishmaniosis involve a granulomatous infiltrate around the ducts of lacrimal glands, leading to retrograde dilation and subsequent accumulation of the secretions.[13]

Cryoglobulinemia is well known to cause several interferences in automated hematology analysis. In this case, both pseudoleukocytosis and pseudothrombocytosis are present.

The Urit Smart V5 reported an erroneously high total WBC count, based on optical measurement, and affected by cryoglobulin interference. This analyzer calculates WBC count by impedance and by flow cytometry, the later was the default configuration in our equipment. On the contrary, the reported total WBC of the Sysmex XN-1000V is calculated on the WNR channel, and no cryoglobulin interference has been observed. With regard to the WBC differential, both analyzers employ flow cytometry. Notable interference that invalidates all WBC differential calculations is observed only in the Urit Smart V5, which utilizes solely light scatter properties without fluorescence. In contrast, the interference observed in the Sysmex XN-1000V, which employs both light scatter properties and fluorescence in the WDF channel, is limited to interference with eosinophil calculation. The aberrant morphology of the WDF channel following warming of the sample has been attributed to the poorly preserved WBC of the sample, which on the blood smear showed prominent blue-proteinaceous material phagocytoses (this could have increased the fluorescence intensity on the scattergram). This phenomenon of cryoglobulin phagocytosis has already been described in the literature.[15] The mild leukopenia observed in this case, in the absence of a decrease in any of the specific WBC types, is of limited clinical significance.

The RBC parameters appear to be unaffected by the cryoglobulins in both analyzers. Regarding RBC morphology, some reports indicate that RBC poikilocytosis in cryoglobulinemic cases corrects after warming the blood to 37°C.[16] However, this did not occur in our case, potentially due to the presence of residual cryoprecipitates (visible on the blood smear) and/or due to the analysis of warm blood being conducted after more than 24 hours after collection.

The two main differential diagnoses for the moderate regenerative anemia are blood loss (which is not clinically evident) or hemolysis. Although the poikilocytosis (acanthocytosis, schistocytosis) is suggestive of RBC fragmentation, it has been considered a most likely *in vitro* artifact. However, it is possible that some degree of clinical RBC fragmentation may be occurring in this dog, and therefore evaluation of a directly extracted blood sample with a warmed syringe should be conducted to definitively determine the presence of poikilocytosis. Although cold agglutinin was not excluded with a Coombs test in our case, it seems unlikely given the absence of microscopic RBC agglutination on the blood smear.

Pseudothrombocytosis represents one of the most prominent interferences of cryoglobulinemia. Other causes of falsely increased platelet count include small, fragmented, or hemolyzed erythrocytes, leukocyte fragments (from normal or leukemic cells), or particulate cellular debris including bacteria, protozoa, fungi or lipids.[17]

The platelet count calculated by impedance on both analyzers is aberrantly high, and corrects after warming the sample to 37°C. Spurious impedance count with a surplus of small particles (left side) is suggestive of cryoprecipitates,[2,18] see platelet histograms above. Our fluorescent optical platelet determination on the RET channel exhibited a spuriously increased count, contrary to other reports in which the Sysmex XE-2100 and Sysmex XN-9000 was not affected in the same channel.[15,16] Other authors have described interferences similar to ours (in impedance and optical platelet counts), but not when using immunoplatelet count with CD61 labeling on a CELL-DYN CD4000 system (Abbott Laboratories).[19] The Sysmex PLT-F channel uses a fluorescent oxazine dye that binds preferentially to platelet organelles that are rich in nucleic acids, such as ribosomes and mitochondria.[20] These staining properties allow to clearly differentiate between platelets and small particles like RBC fragments.[20,21] The PLT-F channel differentiation between platelets and WBC fragments is still controversial, with some studies claiming no interference[20] and others claiming interference.[22,23] In accordance with other reports,[2] the PLT-F channel is useful for platelet determination in cases of cryoglobulinemia and does not suffer from interference.

A definitive assessment of the platelet count in this case was not possible due to the presence of platelet aggregation on the blood smear. However, the count of PLT-F together with the moderate number of medium to large platelet clumps on the blood smear makes it suspect from a normal count, although a mild thrombocytopenia cannot be definitively excluded. Examination of a new sample would be beneficial.

In this case, the cryoglobulin deposits were clearly visible on the blood smear. They were very abundant, proteinaceous, homogeneously distributed, bluish to grayish and amorphous to globular. Several cryoglobulin deposit morphologies have been described, including needle-shaped crystals, amorphous, and roundish deposits.[15]

In conclusion, we describe the first case of a dog infected with *Leishmania infantum* associated with monoclonal hypergammaglobulinemia and cryoglobulinemia. It is important to be aware of the several false alterations induced by cryoglobulins on automated hematology analysis and to be able to identify them. A detailed description of the interference of cryoglobulin with Urit Smart V5 and Sysmex XN-1000V, along with the usefulness of Sysmex PLT-F in this condition, is presented here.

References

1. Desbois AC, Cacoub P, Saadoun D. Cryoglobulinemia: An update in 2019. *Joint Bone Spine*. 2019;86(6):707-713.
2. Baccini V, Geneviève F, Jacqmin H, et al. Platelet counting: Ugly traps and good advice. Proposals from the French-speaking cellular hematology group (GFHC). *J Clin Med*. 2020;9(3).
3. Giraudel JM, Jean-Pierre Pagès D, Guelfi JF. Monoclonal Gammopathies in the Dog: A Retrospective Study of 18 Cases (1986-1999) and Literature Review. *J Am Anim Hosp Assoc*. 2002;38:135-147.
4. Braund KG, Everett RM, Bartels JE, De Buysscher E. Neurologic complications of IgA multiple myeloma associated with cryoglobulinemia in a dog. *J Am Vet Med Assoc*. 1979;174(12):1321-1325.

5. Virella G, Slappendel RJ, Goudswaard J. Multiple myeloma, IgA cryoglobulinemia and serum hyperviscosity in a dog. *Int Arch Allergy Immunol*. 1977;55(1-6):537-541.
6. Hoenig M. Multiple myeloma associated with the heavy chains of immunoglobulin A in a dog. *J Am Vet Med Assoc*. 1987;190(9):1191-1192.
7. Hurvitz AI, MacEwen EG, Middaugh CR, Litman GW. Monoclonal cryoglobulinemia with macroglobulinemia in a dog. *J Am Vet Med Assoc*. 1977;170(5):511-513.
8. Poulaki A, Stergiou IE, Voulgarelis M. Leishmaniasis with cryoglobulinaemia and Leishmania infantum in peripheral blood neutrophils. *Br J Haematol*. 2020;189(5):801.
9. Baneth G, Petersen C, Solano-Gallego L, Sykes JE. Leishmaniosis. In: Sykes JE, ed. *Greene's Infectious Diseases of the Dog and Cat*. Elsevier; 2021:1179-1202.
10. Melendez-Lazo A, Jasensky AK, Jolly-Frahija IT, Kehl A, Müller E, Mesa-Sánchez I. Clonality testing in the lymph nodes from dogs with lymphadenomegaly due to Leishmania infantum infection. *PLoS One*. 2019;14(12).
11. Kolopp-Sarda MN, Miossec P. Practical Details for the Detection and Interpretation of Cryoglobulins. *Clin Chem*. 2022;68(2):282-290.
12. Dammacco R, Cimino L, De Simone L, Alessio G, Dammacco F. Ocular Manifestations of Cryoglobulinemia: a Reappraisal. *Eye (Lond)*. 2024;38(3):585-593.
13. Naranjo C, Fondevila D, Leiva M, Roura X, Peña T. Characterization of lacrimal gland lesions and possible pathogenic mechanisms of keratoconjunctivitis sicca in dogs with leishmaniosis. *Vet Parasitol*. 2005;133(1):37-47.
14. Naranjo C, Fondevila D, Altet L, et al. Evaluation of the presence of Leishmania spp. by real-time PCR in the lacrimal glands of dogs with leishmaniosis. *Veterinary Journal*. 2012;193(1):168-173.
15. Dave RG, Padiyar S, Mathew J, Nair SC. Unusual Morphological and Automated Hematology Analyzer Features in 3 Cases of B-cell Malignancy-associated Type I Cryoglobulinemic Vasculitis. *Indian Journal of Hematology and Blood Transfusion*. 2021;37(4):658-663.
16. Keuren JFW, Raijmakers MTM, Oosterhuis WP, Leers MPG. Drastic effects of cryoglobulin on blood cell counts, erythrocyte morphology and M-protein analysis. *Scand J Clin Lab Invest*. 2010;70(6):462-464.
17. Allen J, Stokol T. Thrombocytosis and Essential Thrombocythemia. In: Brooks MB, Harr KE, Seelig DM, Wardrop KJ, Weiss DJ, eds. *Schalm's Veterinary Hematology*. 7th ed. Wiley; 2022:721-730.
18. Zandecki M, Genevieve F, Gerard J, Godon A. Spurious counts and spurious results on haematology analysers: A review. Part I: Platelets. *Int J Lab Hematol*. 2007;29(1):4-20.
19. von Ahsen N, Ehrlich B, Scott CS, Riggert J, Oellerich M. Cryoglobulins Interfere with Platelet Counts by Optical and Impedance Methods but not with the CD61 Immunoplatelet Count. *Clin Chem*. 2001;47(10):1858-1860.
20. Tanaka Y, Tanaka Y, Gondo K, et al. Performance Evaluation of Platelet Counting by Novel Fluorescent Dye Staining in the XN-Series Automated Hematology Analyzers. *J Clin Lab Anal*. 2014;28(5):341-348.
21. Wada A, Takagi Y, Kono M, Morikawa T. Accuracy of a new platelet count system (PLT-F) depends on the staining property of its reagents. *PLoS One*. 2015;10(10).
22. Bobée V, Boutet C, Daliphard S. Acute hyperleukocytic leukemia with numerous blast fragments can mask thrombocytopenia. *Transfusion (Paris)*. 2018;58(8):1833.
23. Hummel K, van Dun LPJM, Sachse M, Beeger C, Hoffmann JJML. Leukocyte fragments may interfere in the fluorescent platelet count of Sysmex XN hematology analyzers. *Int J Lab Hematol*. 2020;42(4):e167-e169.