

PERSISTENT EXCESSIVE THROMBOCYTHAEMIA IN A CAT

E. Hooijberg¹, M. Pichler², E. Leidinger¹.

¹InVitro Labor, Vienna, Austria.

²Tierklinik Meidling, Vienna, Austria.

Signalment:

7 month-old male neutered DSH

History:

The owner reported inappetance and a swaying gait.

Clinical examination

Clinical examination revealed fever (41°C), hindlimb weakness and ataxia, and oral ulceration and gingivitis.

The cat was unvaccinated.

A blood sample was collected and sent to the InVitro Laboratory for haematology and biochemistry.

Selected laboratory results from the initial presentation are presented in Table 1

Table 1: Laboratory data Day 1

PARAMETER	Day 1	Reference interval
Hct	0.40	0.28-0.47
RBC	9.6	5.5-10.0 x 10 ¹² /L
Hb	119	80-170 g/L
MCV	40	40-55 fl
MCHC	300	310-340 g/L
WBC	1.0	6.0-15.0 x 10 ⁶ /L
Segmented neutrophils	0.2	3.6-10.50 x 10 ⁶ /L
Lymphocytes	0.7	1.0-3.20 x 10 ⁶ /L
Monocytes	0.0	0.0-0.60 x 10 ⁶ /L
Eosinophils	0.1	0.0-0.60 x 10 ⁶ /L
Basophils		0.0-0.30 x 10 ⁶ /L
Thrombocytes	314	200-450 x 10 ⁹ /L
Total protein	85	60-75 g/L

Albumin	31	26-36 g/L
Globulin	54	35-42 g/L
FCoV (IFAT)	negative	
FIV(IC)	negative	
FeLV(ELISA)	negative	

The referring veterinarian subsequently requested a Feline Parvovirus (FPV) titre.

Result: **FPV (IFAT): 1:640 positive**

Five days later the female littermate from the same household of the animal in question presented with similar clinical signs, although without any hindlimb ataxia or weakness. She had been vaccinated once 3 months previously (Feline Rhinotracheitis, Feline Panleukopaenia, Feline Calicivirus) and the course was not completed. A FPV IFAT performed subsequently for this cat revealed a titre of **1:1280**.

Both cats were treated with omega interferon (Virbagen® Omega, Virbac) and seen 10d days later. The hindlimb ataxia noted in the male cat persisted.

Another blood sample was taken from the male cat and sent to our lab. The results can be seen in Table 2. Thirty-five days after first presentation the patient was again examined by the referring veterinarian and a third blood sample evaluated, the results of which are also presented in Table 2.

Table 2: Laboratory data day 10 and day 35

PARAMETER	Day 10	Day 35	Reference interval
Hct	0.29	0.38	0.28-0.47
RBC	6.8	11.1	5.5-10.0x10 ¹² /L
Hb	100	144	80-170 g/L
MCV	42	34	40-55 fl
MCHC	350	380	310-340 g/L
WBC	10.8	17.6	6.0-15.0 x 10 ⁶ /L
Differential			
Band neutrophils	0.0	0.2	0.0-0.6 x 10 ⁶ /L
Segmented neutrophils	7.6	9.5	3.6-10.5 x 10 ⁶ /L
Lymphocytes	2.2	3.9	1.0-3.2 x 10 ⁶ /L
Monocytes	0.8	1.4	0.0-0.6 x 10 ⁶ /L
Eosinophils	0.1	2.5	0.0-0.6 x 10 ⁶ /L
Basophils	0.1	0.2	0.0-0.3 x 10 ⁶ /L
Thrombocytes	3448	4990^a	200-450 x 10 ⁹ /L
Total protein	n.d.	79	60-75 g/L

Albumin	n.d.	30	26-36 g/L
Globulin		49	35-42 g/L
Iron		1.8	1.8-3.2 $\mu\text{mol/L}$
FeLV (IC)		negative	
FCoV (IFAT)		negative	
FPV (IFAT)		1:2560	
Toxoplasma gondii (DA)	1:40	1:40	Borderline titre 1:40
Feline Calicivirus	n.d.	1:320	Borderline titre 1:40
Feline Rhinotracheitis virus	n.d.	negative	

^amanual count using a Neubauer haemocytometer.

Figure 1 shows the CellDyn 3500 histogram for the blood sample from day 10 and Figure 2 is a photograph taken of the sample after centrifugation.

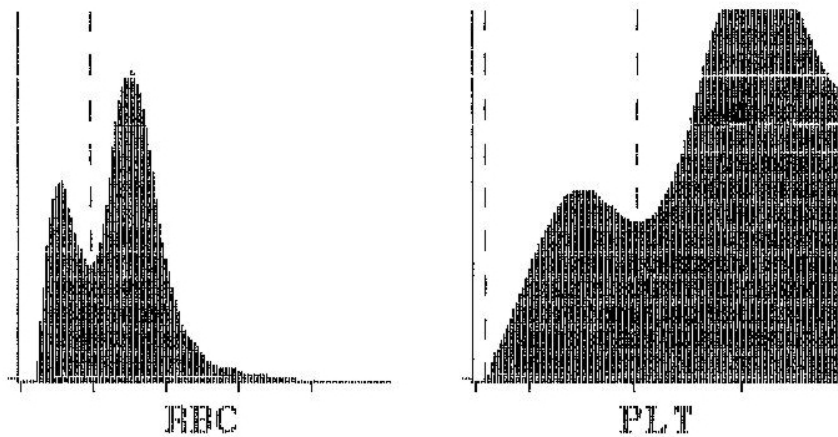


Figure 1: CellDyn 3500 histogram, sample day 10

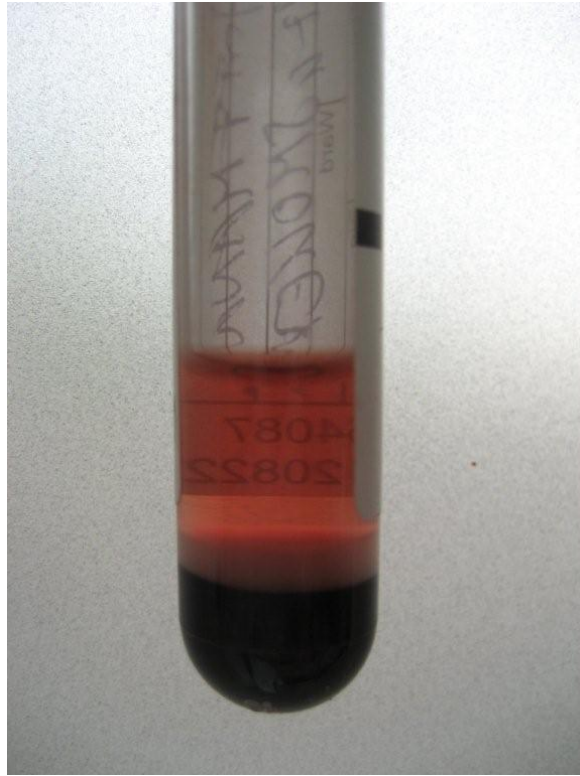


Figure 2: Centrifuged blood sample, day 10.

Description of results

The laboratory results from day 1 indicate a severe leukopenia with a severe neutropenia and moderate lymphopenia, as well as a hyperglobulinaemia. This, together with the unvaccinated status of the animal and the positive test results for FPV lead to a diagnosis of feline panleukopaenia (confirmed by the four-fold rise in titre 10 days later). The hindlimb ataxia and oral ulceration are not completely explained by this diagnosis, it is thought that the cat had a concurrent calicivirus infection which would explain the oral changes. Feline calicivirus can cause lameness due to arthritis and myalgia; this does not fully account for the ataxia.

Subsequent results indicate a resolution of the leukopenia and eventually a mild leukocytosis. The results from day 10 and day 35 show a severe thrombocytosis (in both cases confirmed in the smear and on day 35 by manual counting).

The blood smear from day 10 is shown in Figure 3 and 4 below:

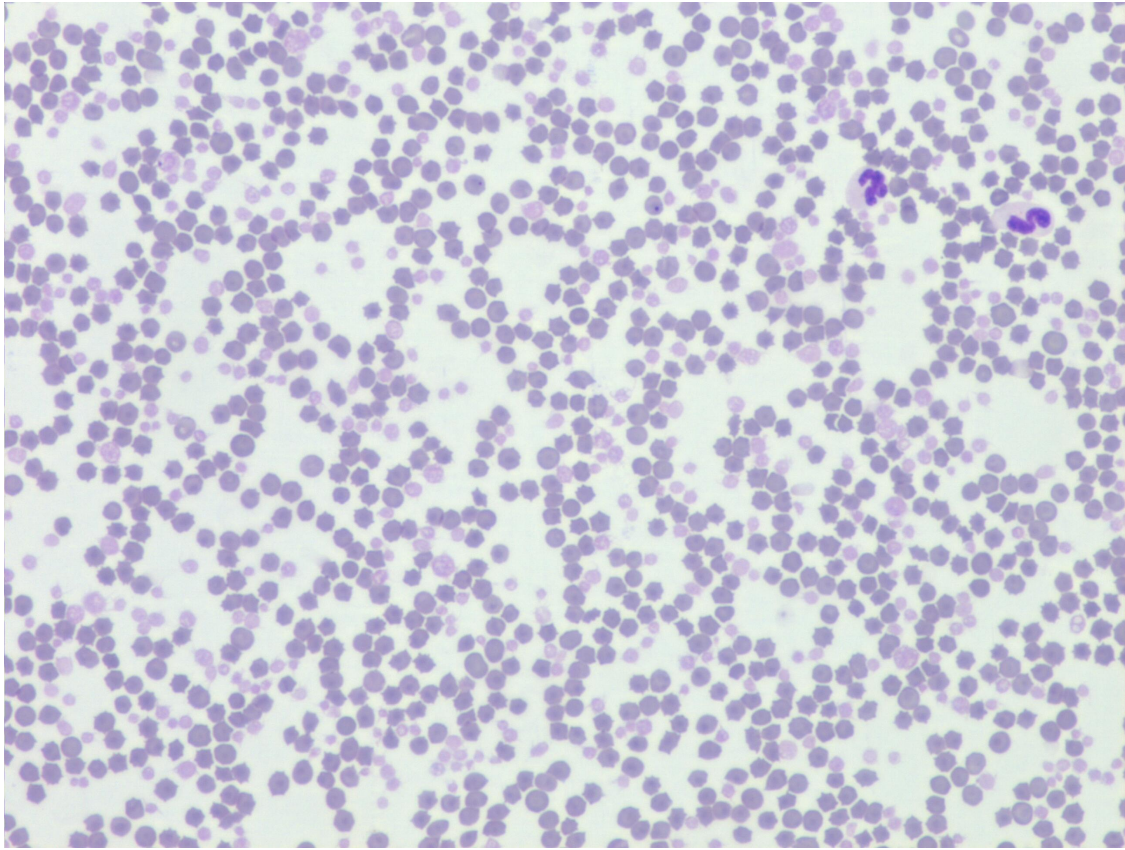


Figure 3: Blood smear day 10, 100x magnification

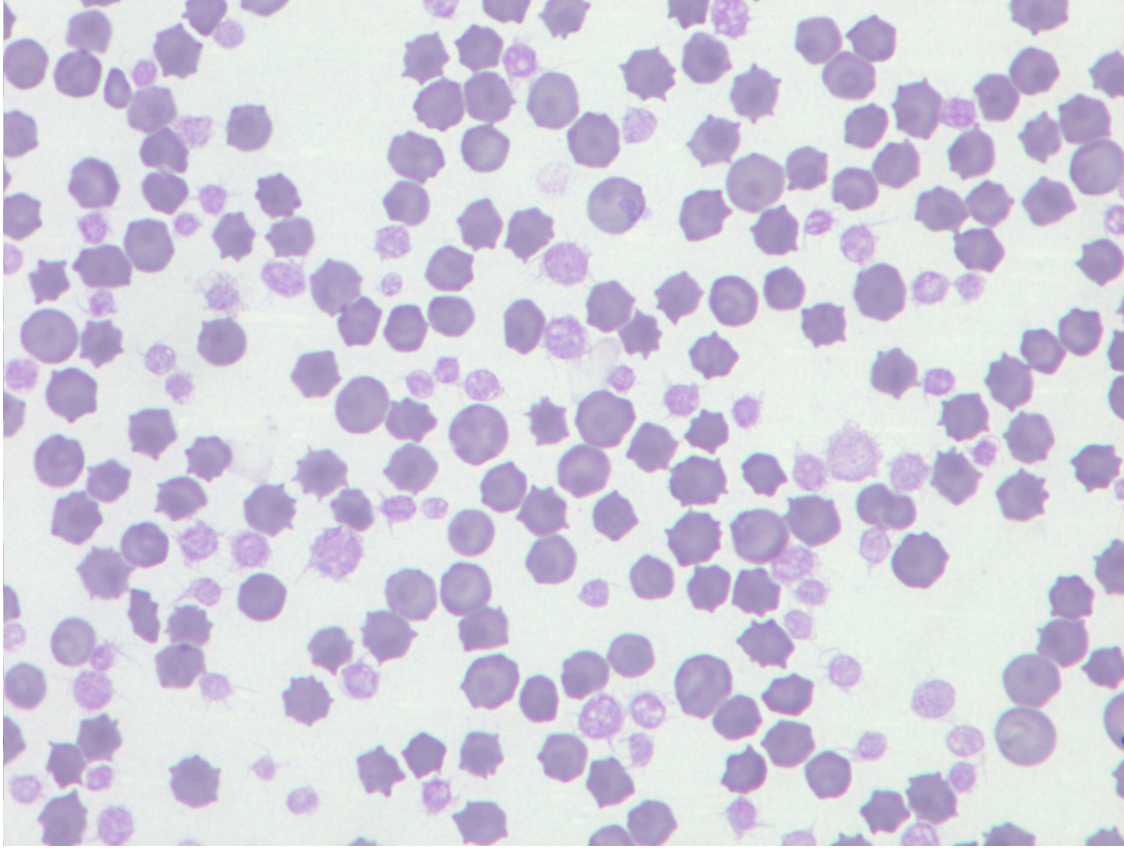


Figure 2: Blood smear day 10, 1000x magnification

Unfortunately permission was not given for bone marrow examination.

Differential diagnoses for thrombocytosis

- 1) Reactive thrombocytosis
- 2) Essential thrombocythaemia (ET)

Discussion

The number of platelets in circulation in a healthy animal depends on negative and positive feedback mechanisms and depends on the rate of production, consumption and destruction. Platelet production consists of megakaryopoiesis and thrombopoiesis. Megakaryopoiesis is stimulated by cytokines including megakaryocyte colony-stimulating factor and thrombopoietin (TPO). Thrombopoiesis, the formation of platelets from megakaryocytes is primarily mediated by TPO. TPO is produced primarily by hepatocytes, but also by renal tubular cells and bone marrow stromal cells^{1,2}.

A negative feedback loop exists between the levels of TPO and the number of platelets: circulating TPO binds to and is taken up by platelets and destroyed. A greater mass of platelets will therefore result in lower levels of TPO which in turn should result in decreased platelet production. In thrombocytopenic states there are fewer platelets to destroy TPO, leading to higher levels and thus increased thrombopoiesis³.

A number of cytokines are released from monocytes and macrophages during inflammation, including interleukin-6 (IL-6). IL-6 has been shown to induce the production of TPO by hepatocytes. This leads to an increase in the thrombocyte count in a process known as reactive thrombocytosis⁴. Reactive thrombocytosis has been described in cats, dogs, horses and other animal species. In cats it has been reported in neoplasia, gastrointestinal disorders, endocrine disorders and corticosteroid and antineoplastic drug use⁵. A recent study of thrombocytosis in cats found reactive thrombocytosis secondary to gastrointestinal, endocrine, cardiovascular, urinary, respiratory, haematological and musculoskeletal diseases⁶. In most of these cases the thrombocyte count was mildly to moderately increased (less than $700 \times 10^9/L$); in the study by Rizzo et al the median count was $801 \times 10^9/L$ with a maximum count of $1895 \times 10^9/L$.

Essential thrombocythaemia (ET) is a rare chronic myeloproliferative disease characterized by the clonal proliferation of the megakaryocytic system resulting in a marked and persistent thrombocytosis in the blood. ET has been reported in a few dogs and cats^{7,8,9}. Platelet counts ranged from $925 \times 10^9/L$ to $4950 \times 10^9/L$ and were accompanied by a regenerative or nonregenerative anemia. Platelets in peripheral blood may show bizarre shapes and be increased in size. Bone marrow exhibits a megakaryocytic hyperplasia, increased platelet budding, erythroid hypoplasia and myeloid hyperplasia. An accompanying basophilia was reported in one dog⁹. ET is a diagnosis of exclusion; in humans a scheme of diagnostic criteria released by the Polycythemia Study Group is used¹⁰. These criteria include: a platelet count of greater than $600 \times 10^9/L$, a haematocrit less than 0.4, stainable bone marrow iron/normal serum ferritin, no or minimal bone marrow fibrosis, no evidence for a myelodysplastic syndrome or cause for reactive thrombocytosis.

In our case, an extreme thrombocytosis (3448 and $4990 \times 10^9/L$) was present on 2 subsequent occasions 15 days apart.

ET was considered unlikely based on the presence of previous inflammatory disease, the speed of onset and the absence of abnormal platelets in the blood smear. A bone marrow examination would have been useful but was not possible.

On the other hand, the pattern of the reaction, i.e. following a viral infection, was typical of a reactive thrombocytosis. However, the severely high platelet counts were unusual. Feline parvovirus causes changes to the bone marrow which include myelophthisis¹¹ which leads typically to a panleukopenia; an associated thrombocytopenia is not reported. Theoretically a myelophthisis associated with parvovirus infection may affect platelet production and a decrease in platelet numbers may occur later in the disease course due to the longer life span of platelets (approximately 10 days). This would result in an increase in TPO levels and a rebound thrombocytosis. IL-6 produced during inflammation would further increase TPO. This cat was treated with Interferon Omega which has been described as causing a mild transient thrombocytopenia in clinical trials in cats¹². This may have also contributed to higher TPO levels and thus an increase in platelet counts.

A blood sample taken 4 months after initial presentation revealed a persistent mild thrombocytosis. ($600 \times 10^9/L$).

Interestingly the blood samples of the littermate of this patient who displayed similar clinical signs and received the same treatment also displayed a thrombocytosis on haematological examination, but it was of short duration and mild ($700 \times 10^9/L$).

The explanation for the severity and relatively long persistence of the thrombocytosis in this interesting case is unclear. A bone marrow examination and measurement of IL-6 and TPO levels may have lead to a clearer explanation of the pathophysiology. Despite his thrombocytosis the cat did not display any signs of a thromboembolic or bleeding disorder and remains healthy.

References:

- 1) Jain N: Essentials of veterinary hematology. (1st ed), 1993, Lea and Febiger, Malvern, pp115-125
- 2) Stockham SL and Scott MA: Fundamentals of Veterinary Clinical Pathology.(2nd ed). 2008, Blackwell Publishing Iowa, pp223-257
- 3). Kaushansky K: The molecular mechanisms that control thrombopoiesis. J. Clin. Invest. 2005;115(12): 3339-3347
- 4). Kaser, A, *et al*. Interleukin-6 stimulates thrombopoiesis through thrombopoietin: role in inflammatory thrombocytosis. Blood. 2001. 98:2720-2725.
- 5). Hammer AS. Thrombocytosis in dogs and cats: A retrospective study. Comp Haematol Int 1991; 1:181-186
- 6) Rizzo F *et al*. Thrombocytosis in cats: a retrospective study of 51 cases (2000-2005). J Feline Med Surg 2007; 9:319-325.
- 7) Hammer AS *et al*: Essential thrombocythemia in a Cat. J Vet Intern Med 1990; 4:87-91
- 8) Dunn JK *et al*: Diagnostic and hematologic features of probable Essential Thrombocythemia in two dogs. Vet. Clin. Path. 28(4):131-138
- 9) Hopper PE *et al*: Probable Essential Thrombocythemia in a Dog. J Vet Intern Med 1989; 3:79-85
- 10) Feldman BF *et al* (eds): Schalm's Veterinary Hematology (5th Ed), 2000. Wiley-Blackwell, pp501-508
- 11) Breuer W *et al*: Bone-marrow changes in infectious diseases and lymphohaemato-poietic neoplasia in dogs and cats – a retrospective study. J Comp Path 1998; 119:57-66
- 12) Information from European Medicines Agency:
<http://www.emea.europa.eu/vetdocs/PDFs/EPAR/virbagenomega/108501en6.pdf>,
(retrieved from the internet 24/08/09)